JOURNEY OF A PATIENT WITH ACUTE ABDOMEN

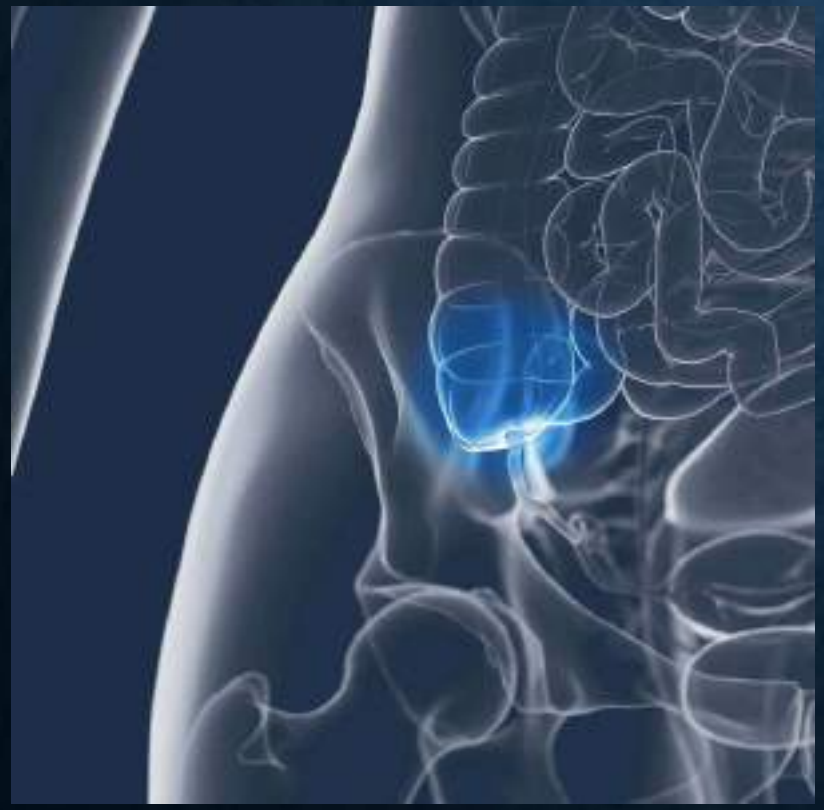

Presented By:

Dr. AYESHA ARMAN

Registrar, Department of Surgery

Green Life Medical College and Hospital

PARTICULARS OF THE PATIENT:

Name:	Md Shaiful Islam
Age:	58 years
Sex:	Male
Religion:	Islam
Address:	Tangail
Marital status:	Married
Occupation:	Ret. Police Inspector
Date of examination:	09-10-2026



1ST VISIT

1ST VISIT: 07/09/2026

- He developed colicky pain in the right iliac fossa and lower back for 3 days for which he attended at upazila health complex, Tangail on 07/09/26.
- He gives history of repeated attack of similar pain for last 4 month which relieved by taking pain killer.
- Here a CBC, CRP and x-ray Pelvis were done.

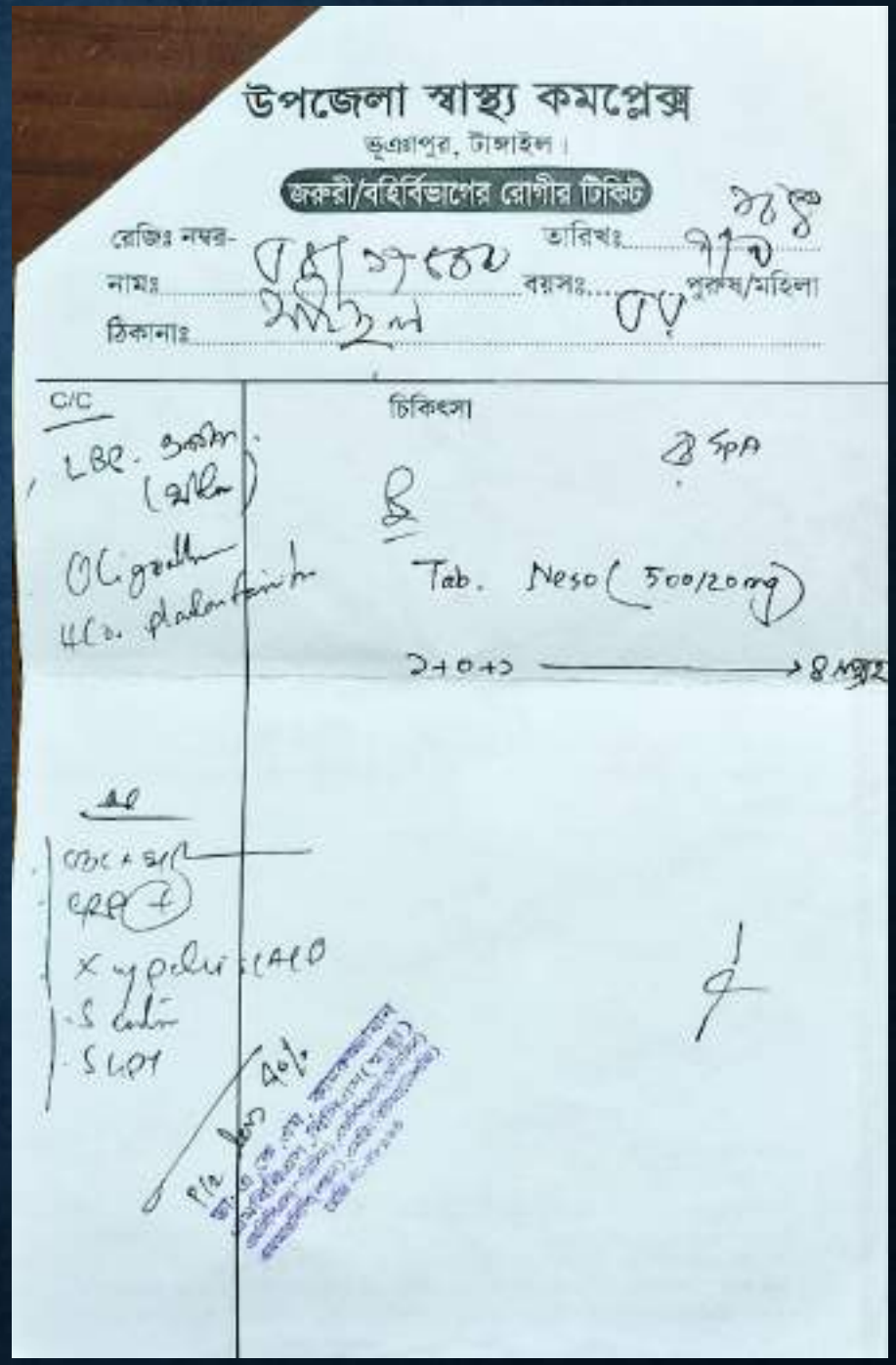

1ST VISIT: 07/09/2026

- CBC:

  Total count of WBC 9.66 k/µL

  Neutrophil 68%



ঢাকা ক্লিনিক এন্ড নার্সিং হোম
Dhaka Clinic & Nursing Home

HAEMATOLOGY REPORT

Test is carried out by Sysmex XN-550

Test	Result	Reference Value
Haemoglobin	13.2 g/dL	
ESR (Capillary Method)	23 mm in 1st hour	
Total Count		
White Blood Cells	9.66 K/µL	
Platelets	171 K/µL	
Red Blood Cells	4.22 M/µL	
Neutrophil	6.59 K/µL	
Lymphocyte	2.63 K/µL	
Monocyte	0.26 K/µL	
Eosinophil	0.27 K/µL	
Basophil		
Differential Count		
Neutrophil	68 %	
Lymphocyte	26 %	
Monocyte	03 %	
Eosinophil	03 %	
Basophil	00 %	
Others		
P.C.V. (HCT)	37.9 %	
M.C.V.	89.8 fL	
M.C.H.	31.3 pg	
M.C.H.C	34.8 g/dL	
M.P.V.	14.1 fL	
P-LCR	66.2 %	
PDW	24.9 (U/GSD)	
PCT	0.24 %	
R.D.W-C.V.	13.5 %	
R.D.W-S.D.	45.1 fL	

Prepared By
MD. KOBIR HOSSAIN

MD. MONZUR RAHMAN (EX-ARMY)

DR. MEER MAHBUB SADIQUE

1ST VISIT: 07/09/2026

- The CRP level was 7.13 mg/L means mildly elevated.



ঢাকা ক্লিনিক এন্ড নার্সিং হোম
Dhaka Clinic & Nursing Home

BIOCHEMISTRY

Patient Name : SAIFUL
Age : 55Y
Gender : Male
Referred By : ASSISTANT, PROF. DR. A. H. M. KAMRUZZAMAN MBBS BCS, MCPS, PCPS, MRCP (MEDICINE), MD(RHEUMATOLOGY)

Test is carried out by Beckman Coulter Au480

Test	Result	Reference Value
This test is run by Neco Card READER II		
CRP (C-Reactive Protein)	7.13 mg/L	< 6 mg/L
ALT (SGPT)	19 U/L	F: <35 U/L, M: <50 U/L
Creatinine	0.85 mg/dL	M 0.7-1.4 F: 0.7-1.2 mg/dL

Prepared By
MD. KOBIR HOSSAIN
Diploma in Path
Medical Technologist (Lab)
Special Trained in CMCH, Tangail
Dhaka Clinic & Nursing Home

MD. MONZUR RAHMAN (EX-ARMY)
Medical Technologist (Class I, AFP)
Diploma in Path
Dhaka Clinic & Nursing Home

DR. MEER MAHBUB SADIQUE
MBBS (DU), MPH(EMU), DMU (DU)
Chief Executive Officer (CEO)
Dhaka Clinic & Nursing Home, Tangail

1ST VISIT: 07/09/2026

- The x-ray Pelvis was normal.



ঢাকা ক্লিনিক এন্ড নার্সিং হোম
Dhaka Clinic & Nursing Home

X- RAY (Digital) REPORT

Invoice No: D2609002380 | Invoice Date: 07/09/2026 04:36 PM | Delivery Date: 08/09/2026
Hospital No: H2609199223 | Report No: | Report Status: FINALIZED
Patient Name: SAIFUL
Age / Gender: 50Y / Male | Patient Status: OPD
Ref. Doctor: ASSISTANT. PROF. DR. A. K. M. KAMRUZZAMAN MBBS.BCS, MCPS, FCPS, MRCP (MEDICINE), M...

Test Name: X-Ray Pelvis AP 100% Digital

Prof. Dr. Upendra Kumar Dey Sarker

1ST VISIT: 07/09/2026

- He was treated conservatively with antibiotics and advised for follow-up after one month.
- Following treatment, his pain mostly subsided.

2ND VISIT

2ND VISIT: 03/10/2026

- After 28 days of 1st visit on 03/10/26 he developed sudden severe colicky abdominal pain & constipation for 3 days and again went to the Upazila health complex, Tangail.

2ND VISIT: 03/10/2026

- USG of whole abdomen done on 04/10/2026.
- Findings: Grade-3 Fatty change in Liver with prostatic lesion (?) with poor corticomedullary differentiation of Rt Kidney with GB sludge.

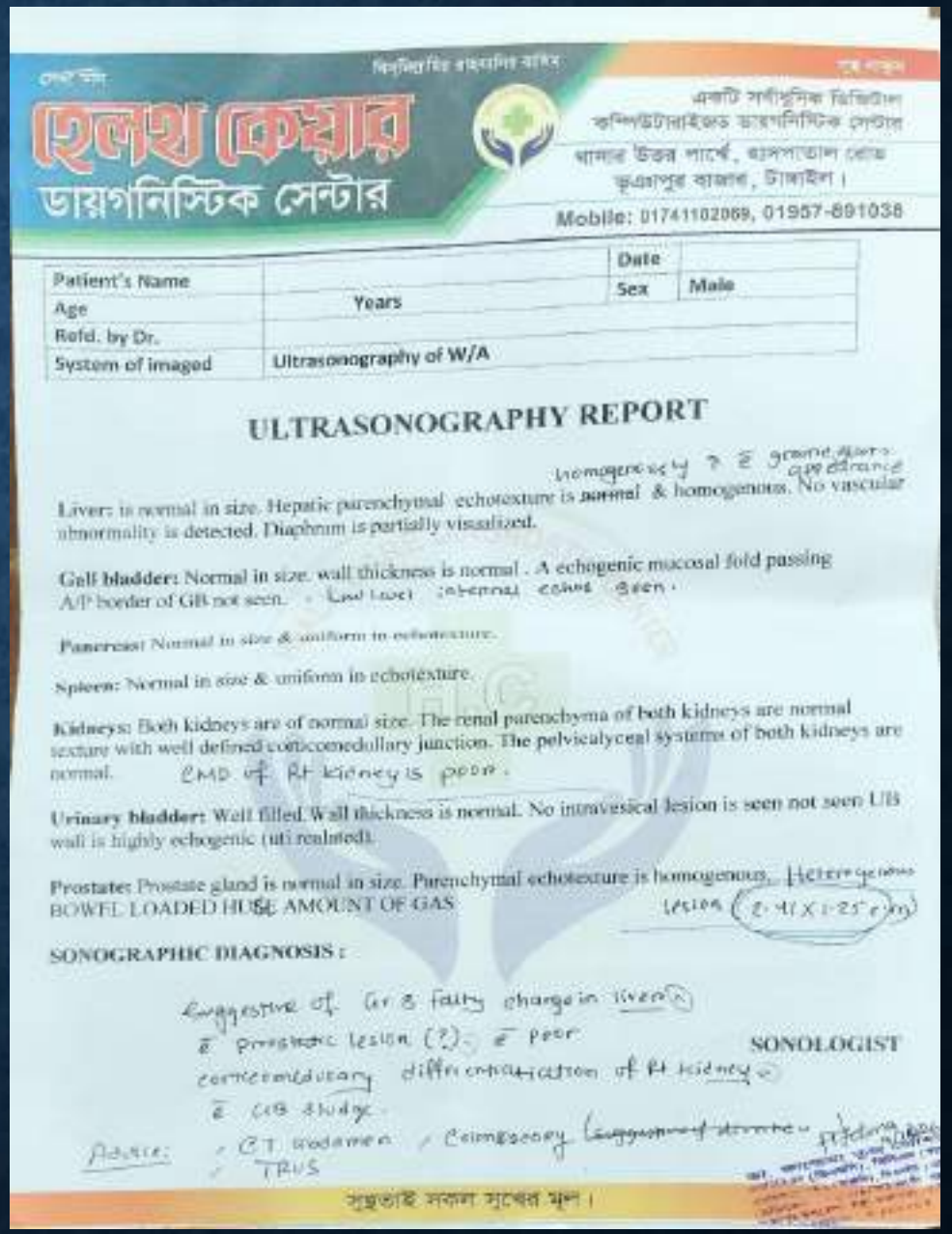

হেলথ কেয়ার
ডায়গনিস্টিক সেন্টার

একটি সার্বজনীক ডিজিটাল
কম্পিউটারাইজড ডায়গনিস্টিক সেন্টার
থানার উত্তর পার্শ্বে, হাসপাতাল মোড়
ভূঞাপুর বাজার, টাঙ্গাইল।
Mobile: 01741102069, 01957-691038

Patient's Name		Date	
Age	Years	Sex	Male
Refd. by Dr.			
System of imaged	Ultrasonography of W/A		

ULTRASONOGRAPHY REPORT

Liver: is normal in size. Hepatic parenchymal echotexture is normal & homogenous. No vascular abnormality is detected. Diaphram is partially visualized.

Gall bladder: Normal in size. wall thickness is normal . A echogenic mucosal fold passing A/P border of GB not seen.

Pancreas: Normal in size & uniform in echotexture.

Spleen: Normal in size & uniform in echotexture.

Kidneys: Both kidneys are of normal size. The renal parenchyma of both kidneys are normal texture with well defined corticomedullary junction. The pelvicalyceal systems of both kidneys are normal.

Urinary bladder: Well filled. Wall thickness is normal. No intravesical lesion is seen not seen UB wall is highly echogenic (uti realated).

Prostate: Prostate gland is normal in size. Parenchymal echotexture is homogenous.
BOWEL LOADED HUGE AMOUNT OF GAS

SONOGRAPHIC DIAGNOSIS :

SONOLOGIST

সুস্থতাই সকল সুখের মূল।

2ND VISIT: 03/10/2026

- He was admitted on 3/10/26 & given conservative treatments and discharged on 5/10/26 with advice for referral to Tangail Medical college hospital.
- But he didn't go there.
- After receiving medication at home he felt better but the pain did not completely subside.

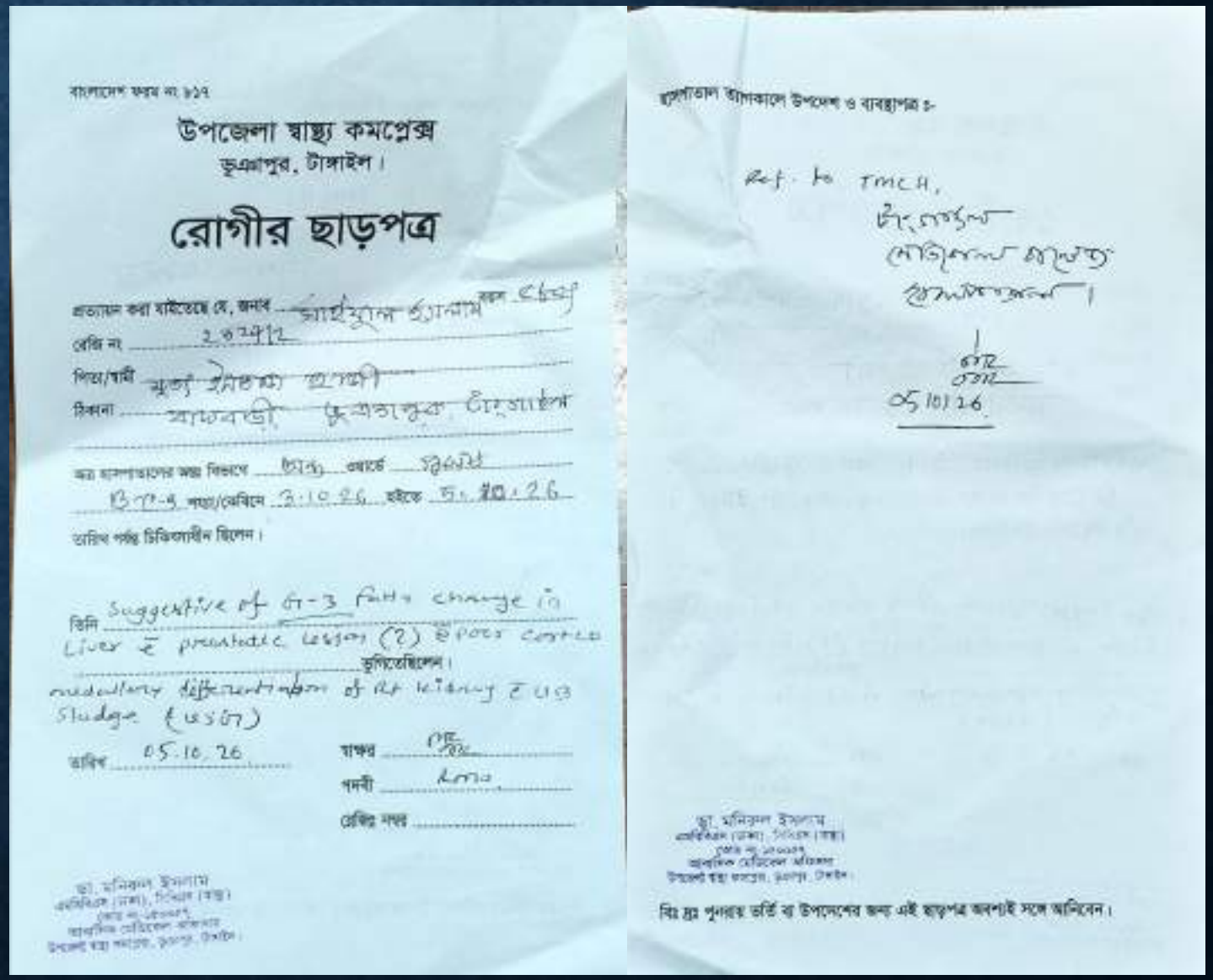

বাংলাদেশ ফরম নং ৮১৭

উপজেলা স্বাস্থ্য কমপ্লেক্স
ভূঞাপুর, টাঙ্গাইল।

রোগীর ছাড়পত্র

প্রত্যায়ন করা যাইতেছে যে, জনাব সাইফুল ইসলাম বয়স [illegible]
রেজি নং [illegible]
পিতা/স্বামী [illegible]
ঠিকানা [illegible]
ক্ষত হাসপাতালের অন্তঃ বিভাগে [illegible] এবার্ডে [illegible]
[illegible] শয্যা/কেবিনে 3.10.26 হইতে 5.10.26
তারিখ পর্যন্ত চিকিৎসাধীন ছিলেন।

তিনি Suggestive of G-3 Fatty change in Liver ē prostatic lesion (?) ē poor cortico medullary differentiation of Rt kidney ē U3 Sludge (USG) ভুগিতেছিলেন।

তারিখ 05.10.26
স্বাক্ষর [illegible]
পদবী [illegible]
রেজিস্ট্রি নম্বর

ডা. মনিরুল ইসলাম
এমবিবিএস (ঢাকা), সিভিল (স্বাস্থ্য)
[illegible]
আন্তরিক মেডিকেল অফিসার
উপজেলা স্বাস্থ্য কমপ্লেক্স, ভূঞাপুর, টাঙ্গাইল।

হাসপাতাল ত্যাগকালে উপদেশ ও ব্যবস্থাপত্র :-

Ref. to TMCH,
টাংগাইল
মেডিকেল কলেজ
হাসপাতাল।

05/10/26

ডা. মনিরুল ইসলাম
এমবিবিএস (ঢাকা), সিভিল (স্বাস্থ্য)
[illegible]
আন্তরিক মেডিকেল অফিসার
উপজেলা স্বাস্থ্য কমপ্লেক্স, ভূঞাপুর, টাঙ্গাইল।

বিঃ দ্রঃ পুনরায় ভর্তি বা উপদেশের জন্য এই ছাড়পত্র অবশ্যই সঙ্গে আনিবেন।

3RD VISIT

3RD VISIT: 05/10/2026

- After 2 days of 2nd visit he visited to Dr. Rajib Karmoker, Urologist, at Medinova Medical services Ltd on 05/10/26 at Tangail.
- He complained of periumbilical pain spreading to the whole abdomen later, scanty micturition and fever for last 1 day.
- Underwent some investigations.

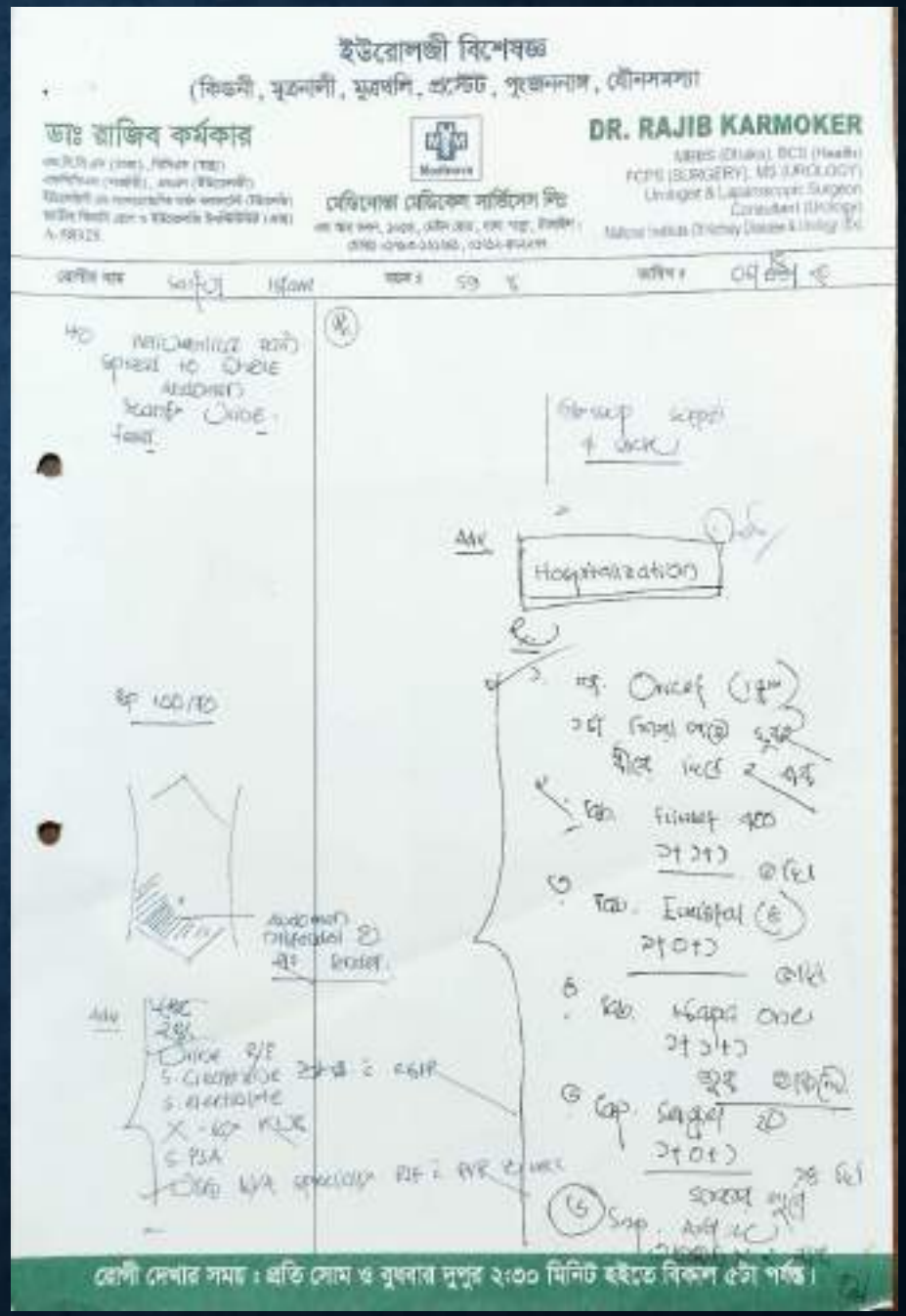

3RD VISIT: 05/10/2026

- CBC:

  The WBC count was 22,100/cumm

  Neutrophil count was 90%

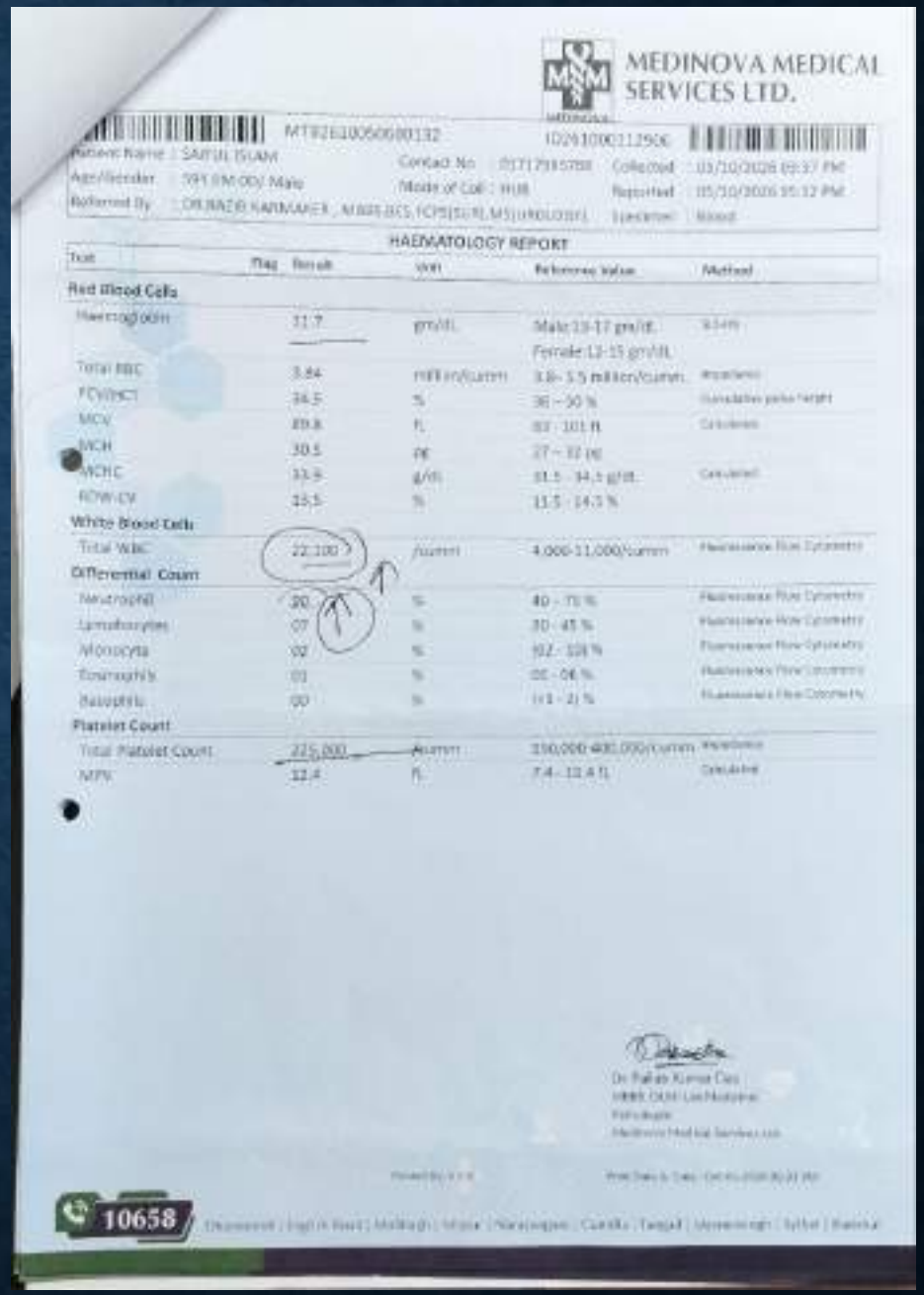

MEDINOVA MEDICAL SERVICES LTD.

HAEMATOLOGY REPORT

Test	Flag	Result	Unit	Reference Value	Method
Red Blood Cells					
Haemoglobin		11.7	gm/dL	Male:13-17 gm/dL Female:12-15 gm/dL	
Total RBC		3.84	million/cumm	3.8- 5.5 million/cumm	
PCV/HCT		34.5	%	36 – 50 %	
MCV		89.8	fL	83 - 101 fl	
MCH		30.5	pg	27 – 32 pg	
MCHC		33.9	g/dL	31.5 - 34.5 g/dL	
RDW-CV		15.5	%	11.5 - 14.5 %	
White Blood Cells					
Total WBC		22,100	/cumm	4,000-11,000/cumm	
Differential Count					
Neutrophil		90	%	40 - 75 %	
Lymphocytes		07	%	20 - 45 %	
Monocyte		02	%	02 - 10 %	
Eosinophils		01	%	00 - 06 %	
Basophils		00	%	00 - 02 %	
Platelet Count					
Total Platelet Count		225,000	/cumm	150,000-400,000/cumm	
MPV		12.4	fL	7.4 - 12.4 fL	

Dr. Pallab Kumar Das
MBBS, DMU (Lab Medicine)
Pathologist
Medinova Medical Services Ltd.

10658

3RD VISIT: 05/10/2026

- Urine R/M/E:

  Pus cell- 26-28 /hpf

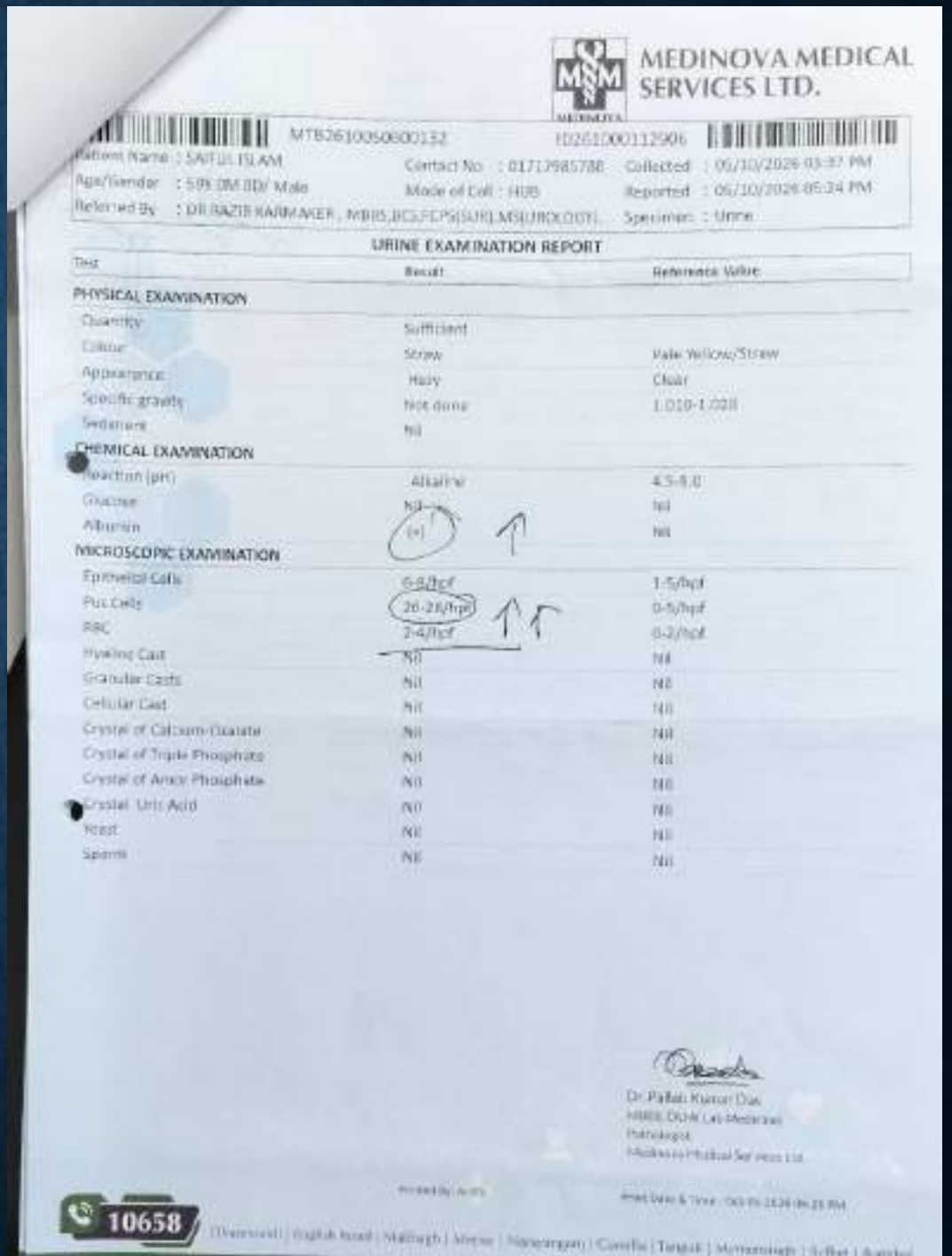

MEDINOVA MEDICAL SERVICES LTD.

MTB2610050600132 H02610001112906

Patient Name : SAIFUL ISLAM Contact No : 01713985788 Collected : 05/10/2026 03:37 PM

Age/Gender : 59 YR 0M 0D/ Male Mode of Coll : HOS Reported : 05/10/2026 05:24 PM

Referred By : DR.RAZIB KARMAKER , MBBS,BCS,FCPS(SURG),MS(UROLOGY) Specimen : Urine

URINE EXAMINATION REPORT

Test	Result	Reference Value
PHYSICAL EXAMINATION		
Quantity	Sufficient	
Colour	Straw	Pale Yellow/Straw
Appearance	Hazy	Clear
Specific gravity	Not done	1.010-1.020
Sediment	Nil	
CHEMICAL EXAMINATION		
Reaction (pH)	Alkaline	4.5-8.0
Glucose	Nil	Nil
Albumin	(+)	Nil
MICROSCOPIC EXAMINATION		
Epithelial Cells	6-8/hpf	1-5/hpf
Pus Cells	26-28/hpf	0-5/hpf
RBC	2-4/hpf	0-2/hpf
Hyaline Cast	Nil	Nil
Granular Casts	Nil	Nil
Cellular Cast	Nil	Nil
Crystal of Calcium Oxalate	Nil	Nil
Crystal of Triple Phosphate	Nil	Nil
Crystal of Amor Phosphate	Nil	Nil
Crystal Uric Acid	Nil	Nil
Yeast	Nil	Nil
Sperm	Nil	Nil

Dr. Pallab Kumar Das
MBBS, DCP, Lab Medicine
Pathologist
Medinova Medical Services Ltd.

10658

3RD VISIT: 05/10/2026

- USG of whole abdomen:

  - Excess gas & fecal matter containing bowel loops.

  - Urinary floating echoes.



MEDINOVA MEDICAL SERVICES LTD.

Prostate

Seminal vesicles

"Excess gas & fecal matter containing bowel loops are noted."

Impression:

- Urinary floating echoes likely represent tissue debris / mucus / cells / crystals.
- Excess gas & fecal matter containing bowel loops.
- Significant PVR.

10658

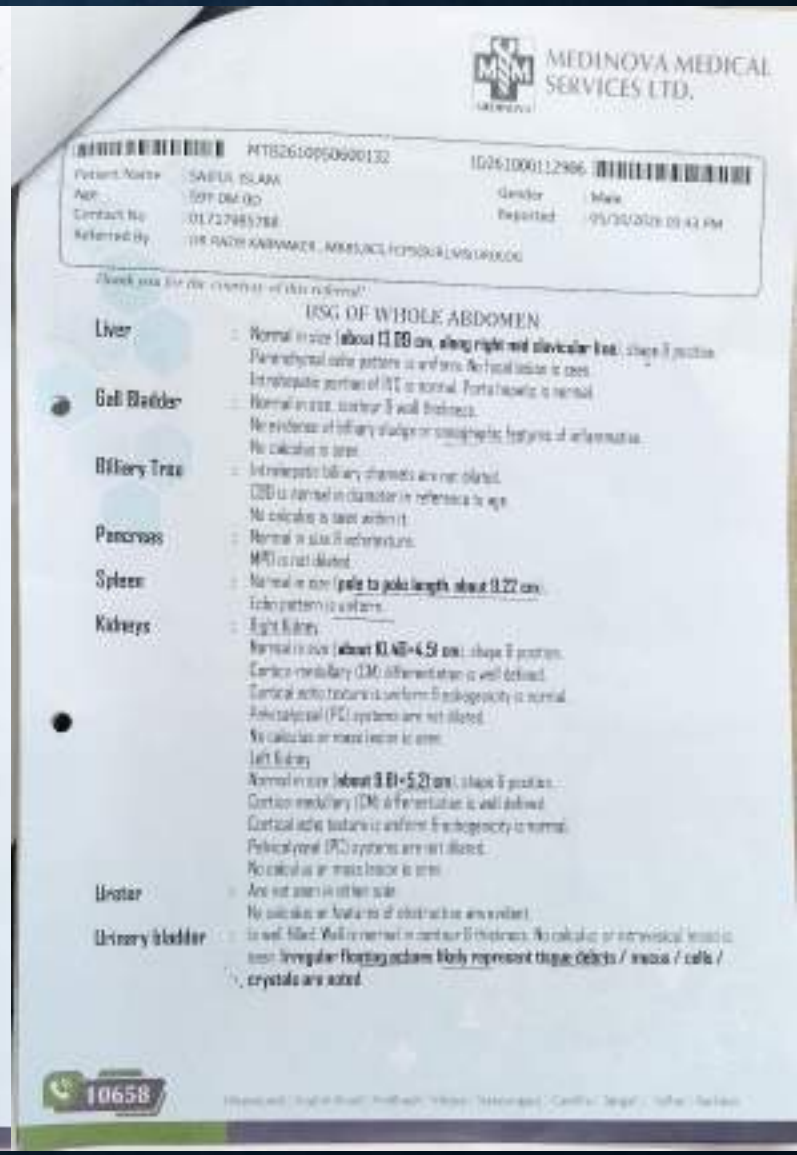

MEDINOVA MEDICAL SERVICES LTD.

USG OF WHOLE ABDOMEN

Liver

Gall Bladder

Biliary Tree

Pancreas

Spleen

Kidneys

Ureter

Urinary bladder

Irregular floating echoes likely represent tissue debris / mucus / cells / crystals are noted.

10658

3RD VISIT: 05/10/2026

- X-ray KUB: Normal



MEDINOVA MEDICAL SERVICES LTD.

KUB A/P:

The fine detail is obscured by bowel gas and faecal matter.

However, no definite radio opaque calculus or any mass shadow is seen in the KUB region.

Impression: Normal findings.

10658



3RD VISIT: 05/10/2026

- He was prescribed antibiotics and advised for Hospitalization
- He refused admission and went back to home .
- He felt better after taking medication but the pain did not completely subside.

4TH VISIT

4TH VISIT: 08/10/26

- After 3 days of 3rd visit he came to Dhaka and visited to the Dr. Ahmed Ali Molla, Medicine specialist, at Dhaka Lab Bhaban on 08/10/26.
- He complaints of same type of abdominal pain which became severe with abdominal distension, constipation and fever for last 1 day.
- He underwent some investigations

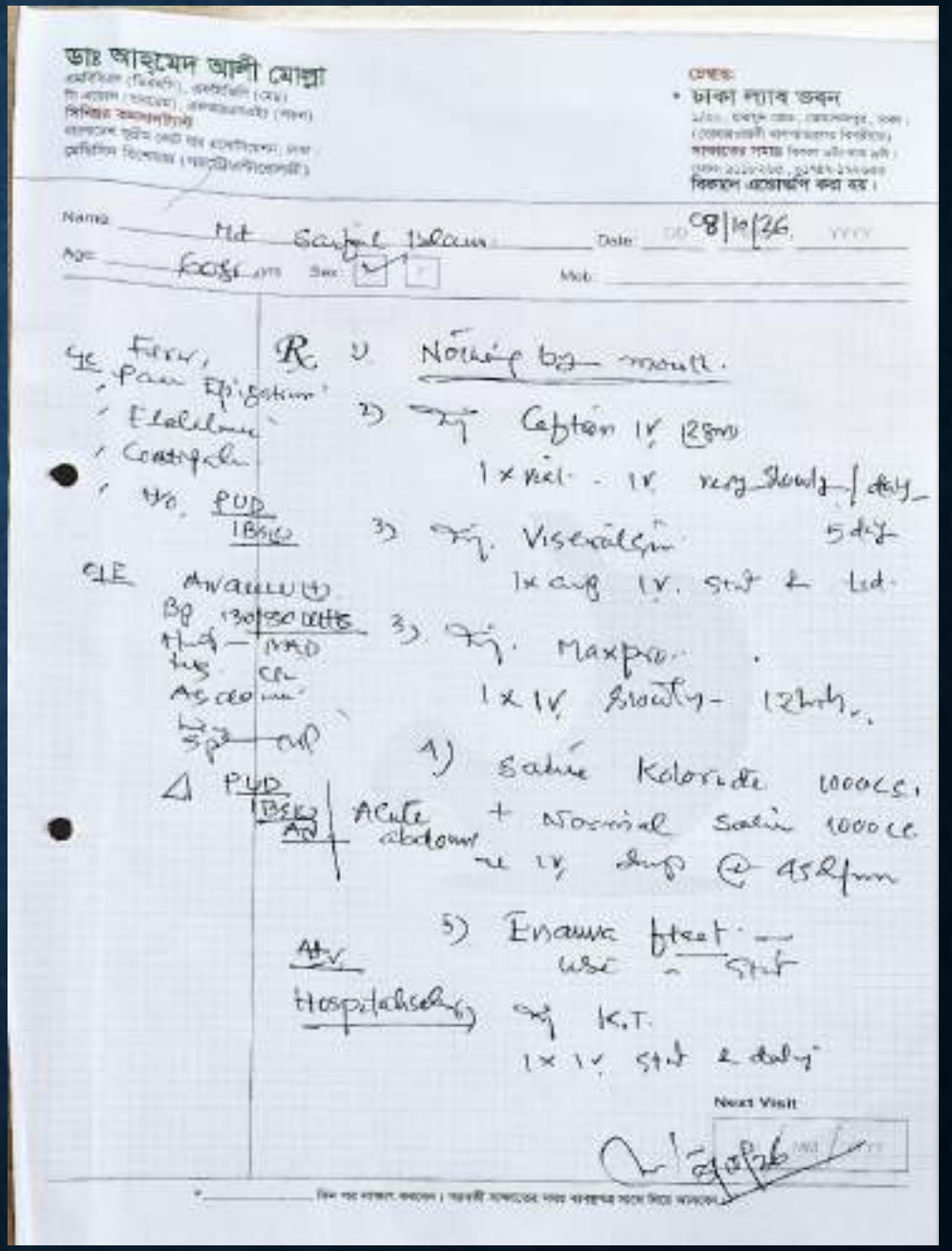

4TH VISIT: 08/10/26

- Plain X-ray abdomen in erect posture:

  Intestinal Obstruction

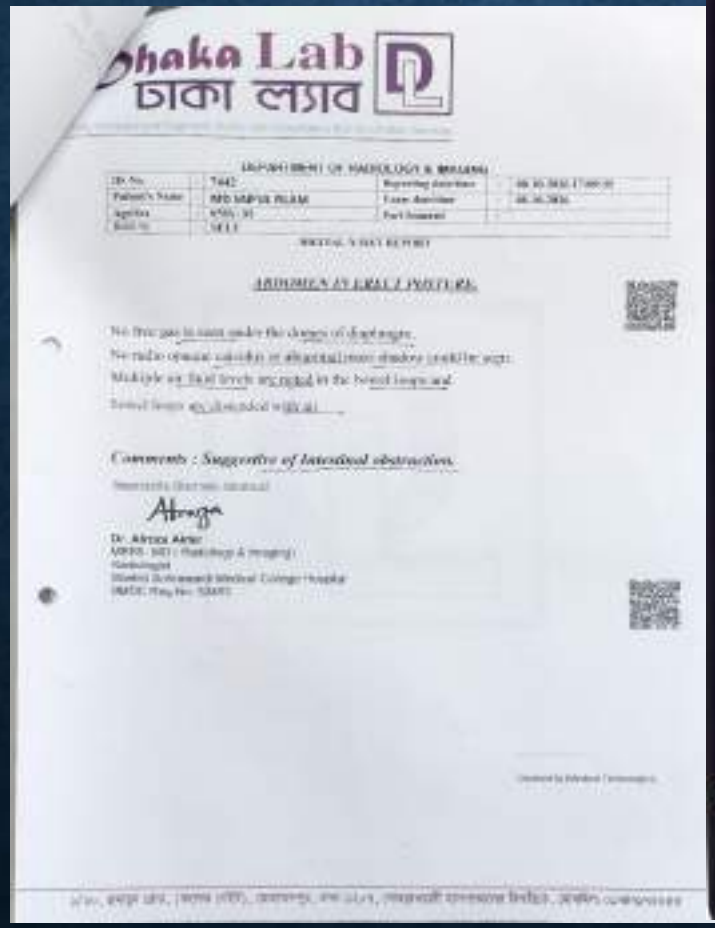
Dhaka Lab
ঢাকা ল্যাব

ABDOMEN IN ERECT POSTURE.

Comments : *Suggestive of Intestinal obstruction.*

Dr. Afroza Akter



4TH VISIT: 08/10/26

- USG of whole abdomen:

  - Mildly distended intestinal lumen with excess gas collection.

  - No sign of biliary obstruction.

  - KUB appears normal.

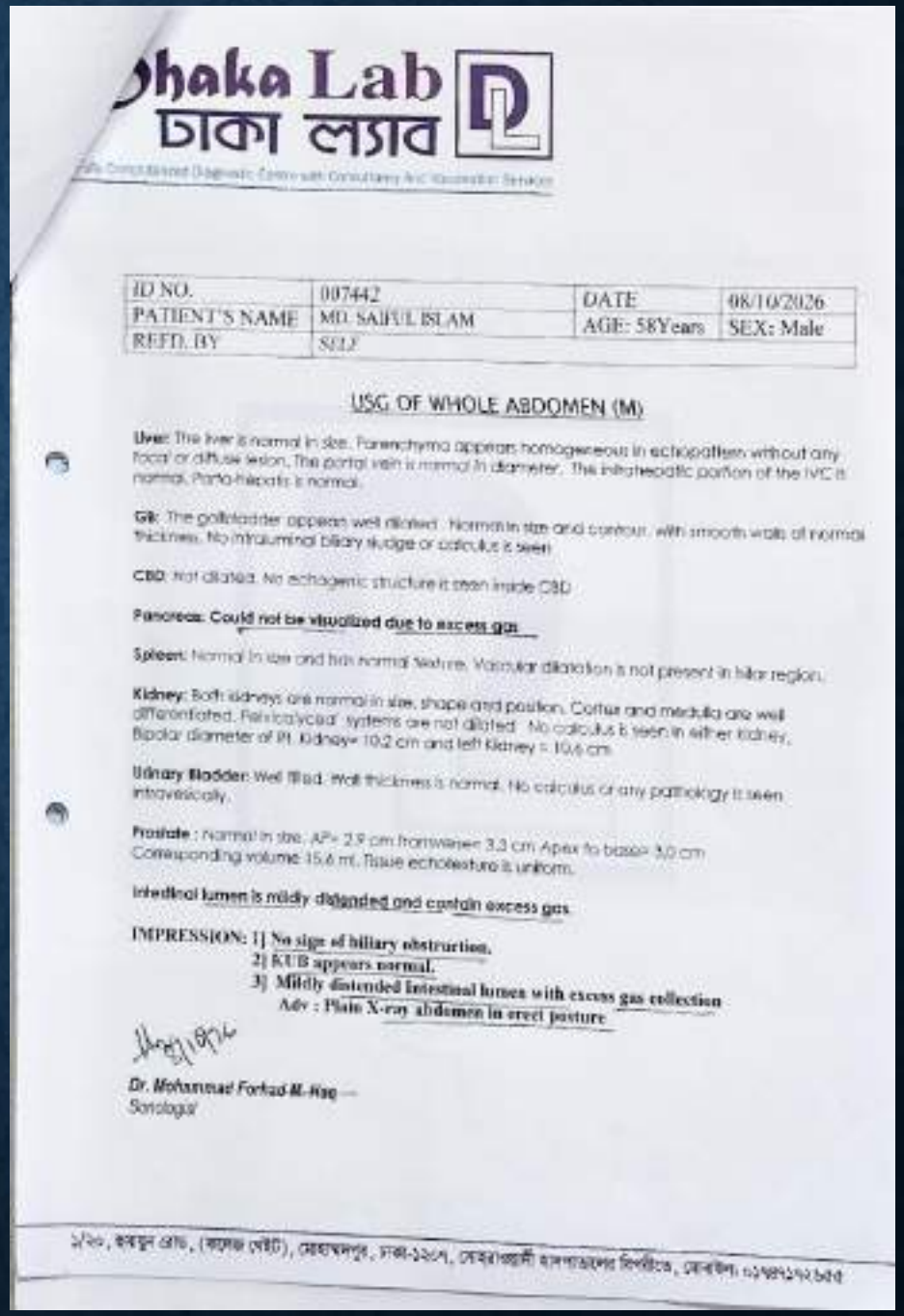

Dhaka Lab
ঢাকা ল্যাব

ID NO.	007442	DATE	08/10/2026
PATIENT'S NAME	MD. SAIFUL ISLAM	AGE: 58Years	SEX: Male
REFD. BY	SELF		

USG OF WHOLE ABDOMEN (M)

Liver: The liver is normal in size. Parenchyma appears homogeneous in echopattern without any focal or diffuse lesion. The portal vein is normal in diameter. The intrahepatic portion of the IVC is normal. Porta-hepatis is normal.

GB: The gallbladder appears well dilated. Normal in size and contour, with smooth walls of normal thickness. No intraluminal biliary sludge or calculus is seen.

CBD: Not dilated. No echogenic structure is seen inside CBD.

Pancreas: Could not be visualized due to excess gas

Spleen: Normal in size and has normal texture. Vascular dilatation is not present in hilar region.

Kidney: Both kidneys are normal in size, shape and position. Cortex and medulla are well differentiated. Pelvicalyceal systems are not dilated. No calculus is seen in either kidney. Bipolar diameter of Pt. Kidney= 10.2 cm and left Kidney = 10.6 cm.

Urinary Bladder: Well filled. Wall thickness is normal. No calculus or any pathology is seen intravesically.

Prostate : Normal in size. AP= 2.9 cm transverse= 3.3 cm Apex to base= 3.0 cm Corresponding volume 15.6 ml. Tissue echotexture is uniform.

Intestinal lumen is mildly distended and contain excess gas

IMPRESSION: 1] No sign of biliary obstruction.
2] KUB appears normal.
3] Mildly distended Intestinal lumen with excess gas collection
Adv : Plain X-ray abdomen in erect posture

Dr. Mohammad Forhad M. Haq
Sonologist

4TH VISIT: 08/10/26

- CBC:

  WBC count 15,200 per/cmm

  Neutrophil count 87%

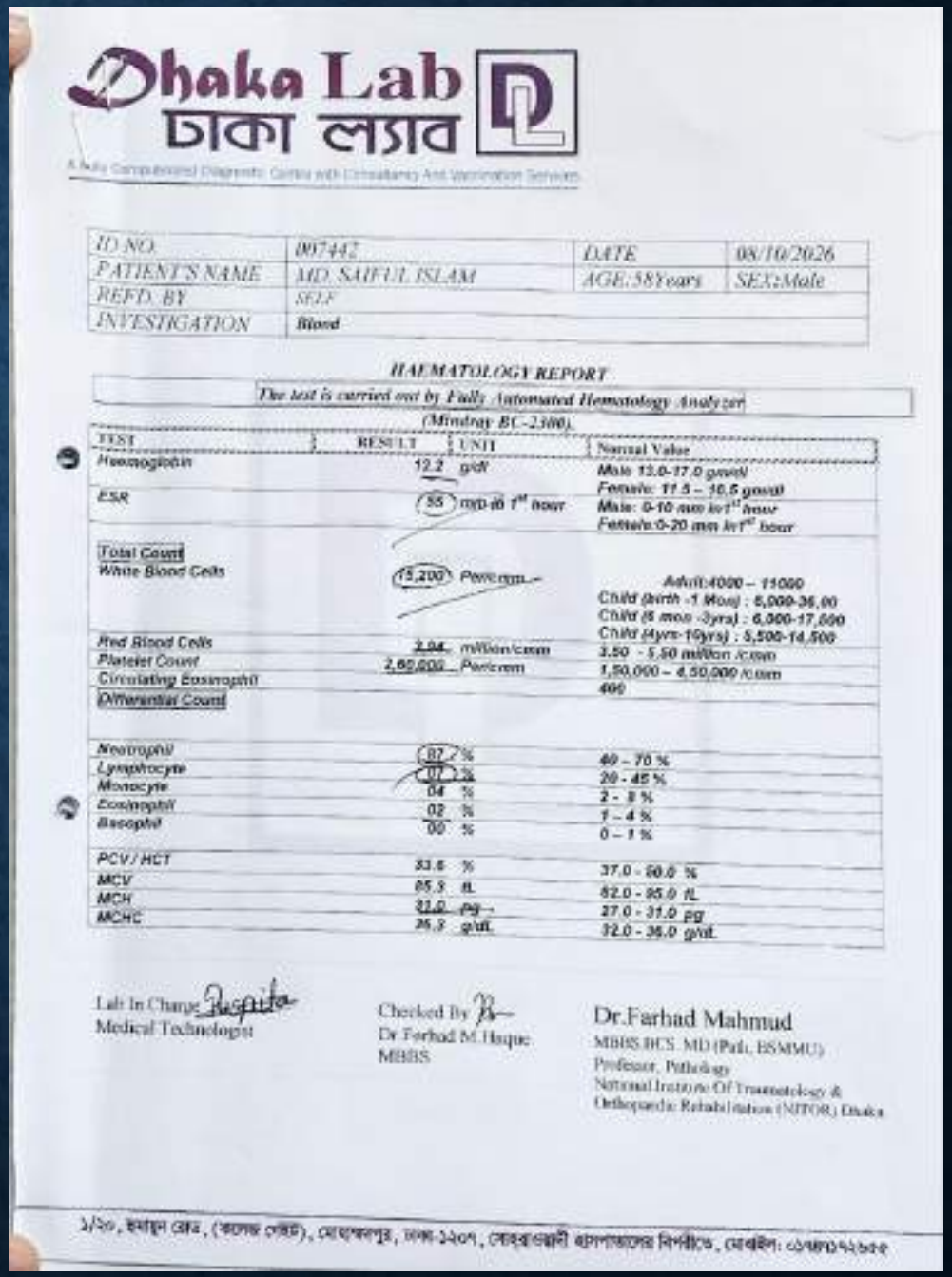

Dhaka Lab
ঢাকা ল্যাব

A Fully Computerized Diagnostic Centre with Consultancy And Vaccination Services

ID NO.	007442	DATE	08/10/2026
PATIENT'S NAME	MD. SAIFUL ISLAM	AGE:58Years	SEX:Male
REFD. BY	SELF		
INVESTIGATION	Blood		

HAEMATOLOGY REPORT

The test is carried out by Fully Automated Hematology Analyzer (Mindray BC-2300).

TEST	RESULT	UNIT	Normal Value
Haemoglobin	12.2	g/dl	Male 13.0-17.0 gm/dl Female: 11.5 – 10.5 gm/dl
ESR	55	mm in 1st hour	Male: 0-10 mm in 1st hour Female:0-20 mm in 1st hour
Total Count White Blood Cells	15,200	Per/cmm	Adult:4000 – 11000 Child (birth -1 Mon) : 6,000-36,00 Child (6 mon -3yrs) : 6,000-17,500 Child (4yrs-10yrs) : 5,500-14,500
Red Blood Cells	2.94	million/cmm	3.50 - 5.50 million /cmm
Platelet Count	2,60,000	Per/cmm	1,50,000 – 4,50,000 /cmm
Circulating Eosinophil			400
Differential Count			
Neutrophil	87	%	40 – 70 %
Lymphocyte	07	%	20 - 45 %
Monocyte	04	%	2 - 8 %
Eosinophil	02	%	1 – 4 %
Basophil	00	%	0 – 1 %
PCV / HCT	33.6	%	37.0 - 50.0 %
MCV	85.3	fL	82.0 - 95.0 fL
MCH	31.0	pg	27.0 - 31.0 pg
MCHC	36.3	g/dL	32.0 - 36.0 g/dL

Lab In Charge
Medical Technologist

Checked By
Dr Farhad M.Haque
MBBS

Dr.Farhad Mahmud
MBBS.BCS. MD (Path, BSMMU)
Professor, Pathology
National Institute Of Traumatology & Orthopaedic Rehabilitation (NITOR) Dhaka

4TH VISIT: 08/10/26

- He was diagnosed as Acute Abdomen and advised for Hospitalization but he refuses admission.

5TH VISIT

5TH VISIT: 08/10/2026

- On the day of 4th visit at 8pm when his condition became worse he admitted to Dhaka Healthcare Hospital under Asso. Prof. Dr. Shafqatul islam on 8/10/26.
- Diagnosed as Intestinal Obstruction.
- Planned for urgent laparotomy.

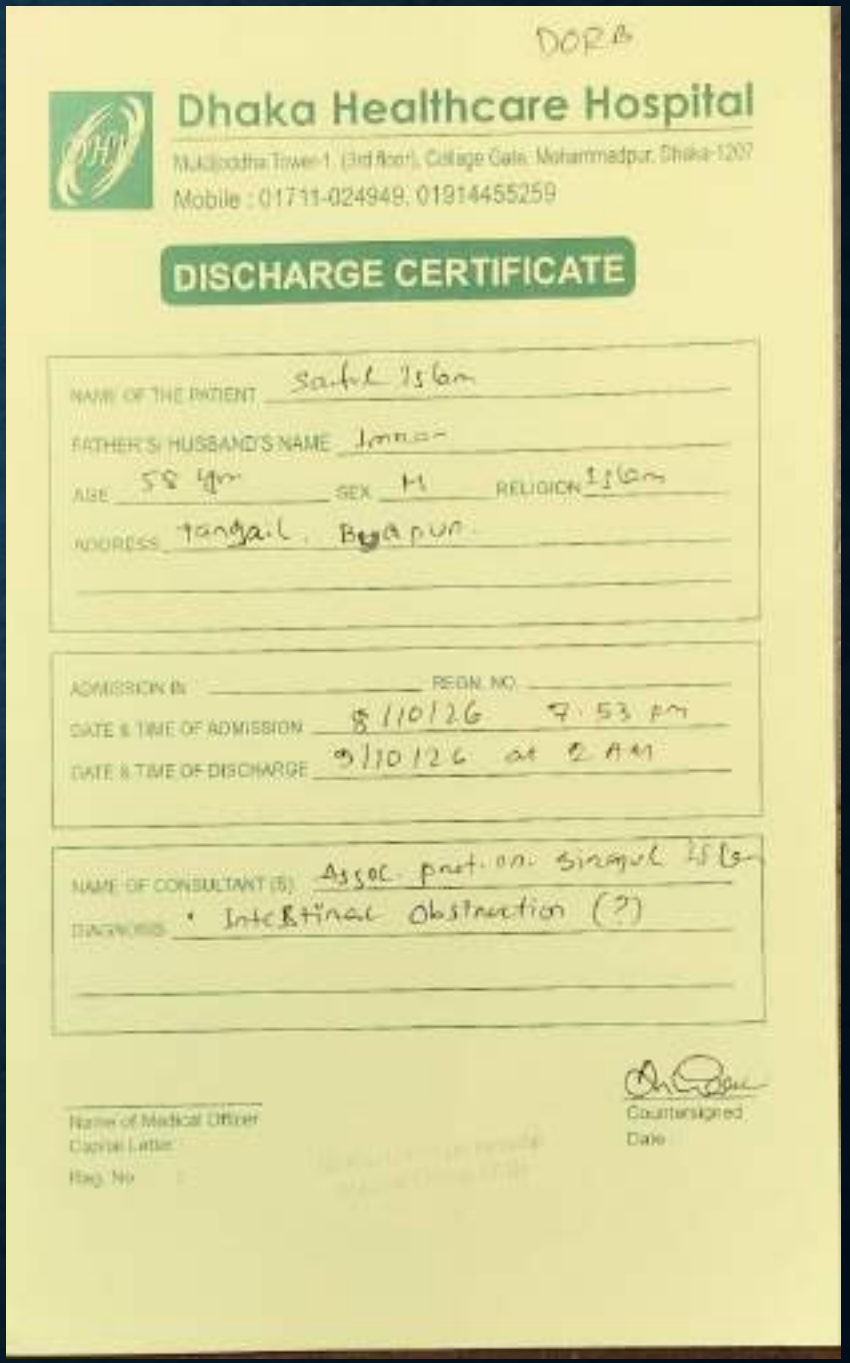

DORB

Dhaka Healthcare Hospital

Mukdjoddha Tower-1, (3rd floor), Collage Gate, Mohammadpur, Dhaka-1207

Mobile : 01711-024949, 01914455259

DISCHARGE CERTIFICATE

NAME OF THE PATIENT Saiful Islam

FATHER'S/ HUSBAND'S NAME Imran

AGE 58 yrs SEX M RELIGION Islam

ADDRESS Tangail, Bijapur

ADMISSION IN REGN. NO.

DATE & TIME OF ADMISSION 8/10/26 7.53 pm

DATE & TIME OF DISCHARGE 9/10/26 at 2 AM

NAME OF CONSULTANT (S) Assoc. prof. Dr. Sirajul Islam

DIAGNOSIS • Intestinal Obstruction (?)

Name of Medical Officer

Capital Letter

Reg. No

Countersigned

Date

5TH VISIT: 08/10/2026

- He took conservative treatment and some amount of stool passed after taking fleet enema.
- He took Discharge On Risk Bond from that Hospital on 09/10/26 at 2am and came directly to the Emergency department of this Green Life Medical College and Hospital.



6TH VISIT

6TH VISIT: 09/10/2026 (AT THIS HOSPITAL)

- He came to emergency Department of Green Life Medical College and Hospital on 9/10/26 at 2:45 am and got admitted under Prof. Dr. Bayezid Hossain sir.
- At the time of admission, he presented to us with the complaint of severe colicky abdominal pain & distension, fever and absolute constipation for last 5 days.
- He was normotensive, non-diabetic, smoker, known case of COPD.

CLINICAL EXAMINATION:

- On examination Pulse 88 b/min, BP 130/70 mm of Hg, Temp 100℃, mildly anaemic and mildly dehydrated.
- The abdomen was distended, muscle guard and lumpy feelings were present in right iliac fossa & lower abdomen, bowel sound was sluggish. D/R/E findings was normal.
- By clinical examination, we suspected a pathology in the right iliac fossa most probably a complication of Acute appendicitis.

INVESTIGATIONS:

Contrast Enhanced CT scan of Whole Abdomen.

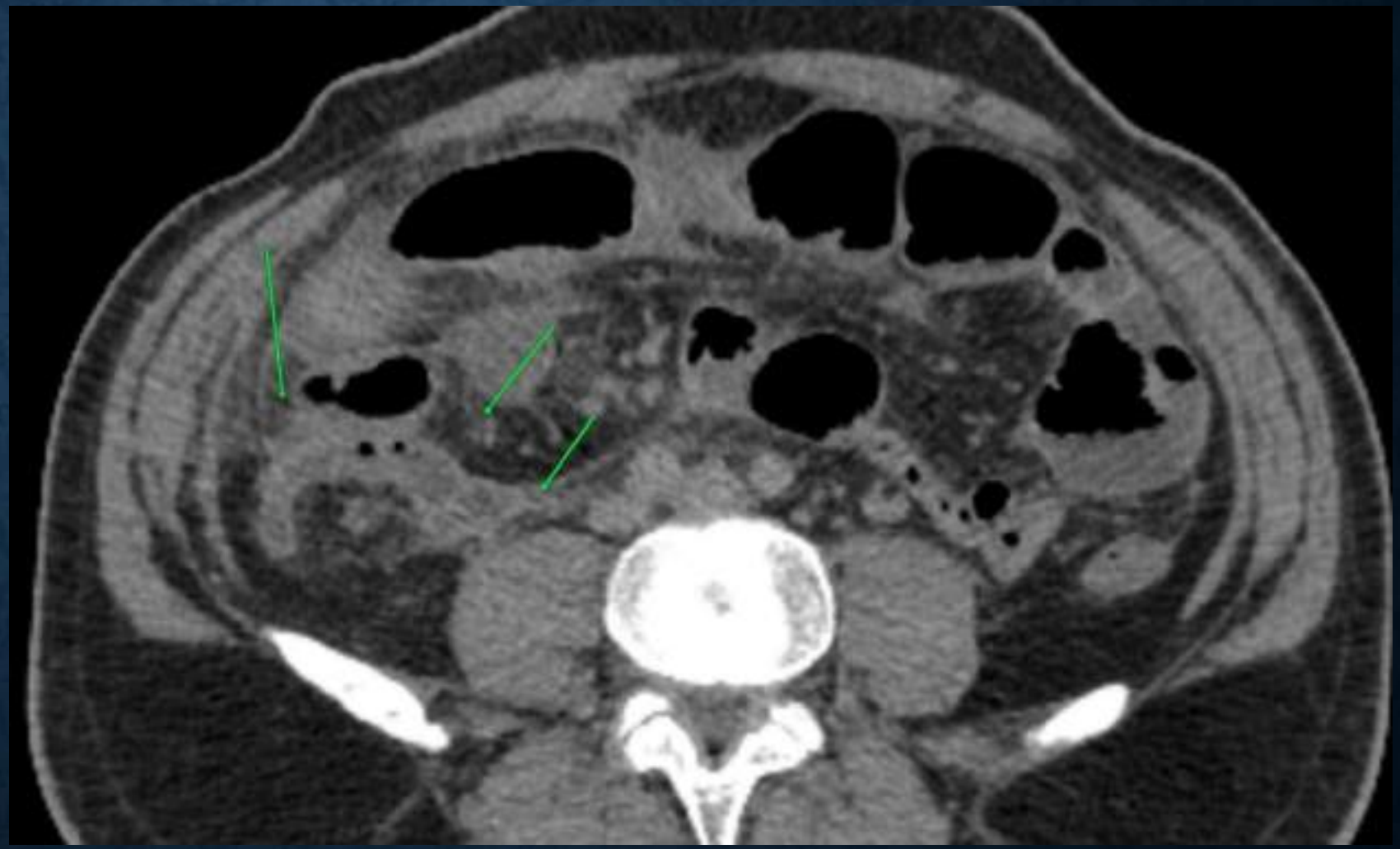

- Burst appendicitis with localized collection

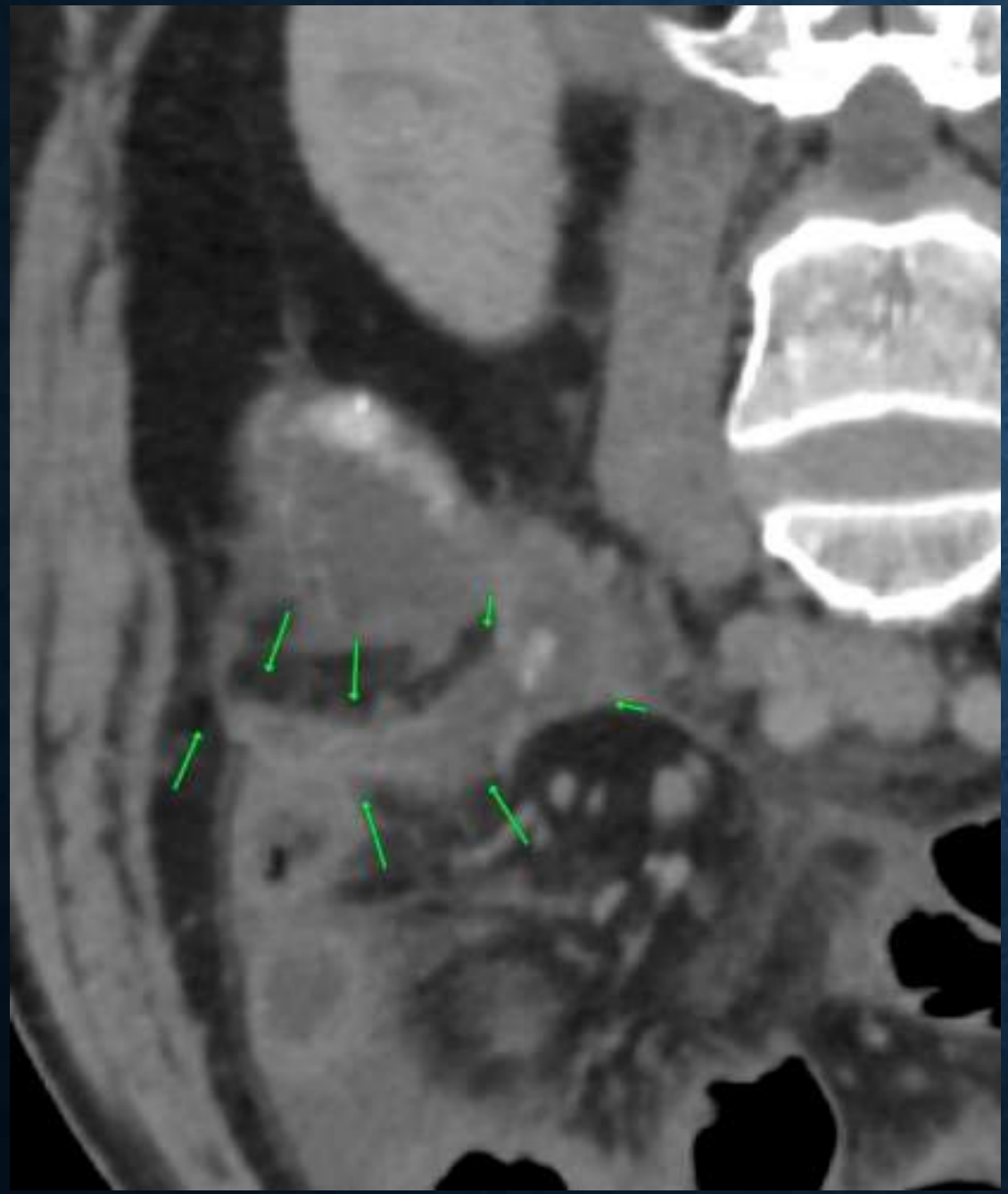

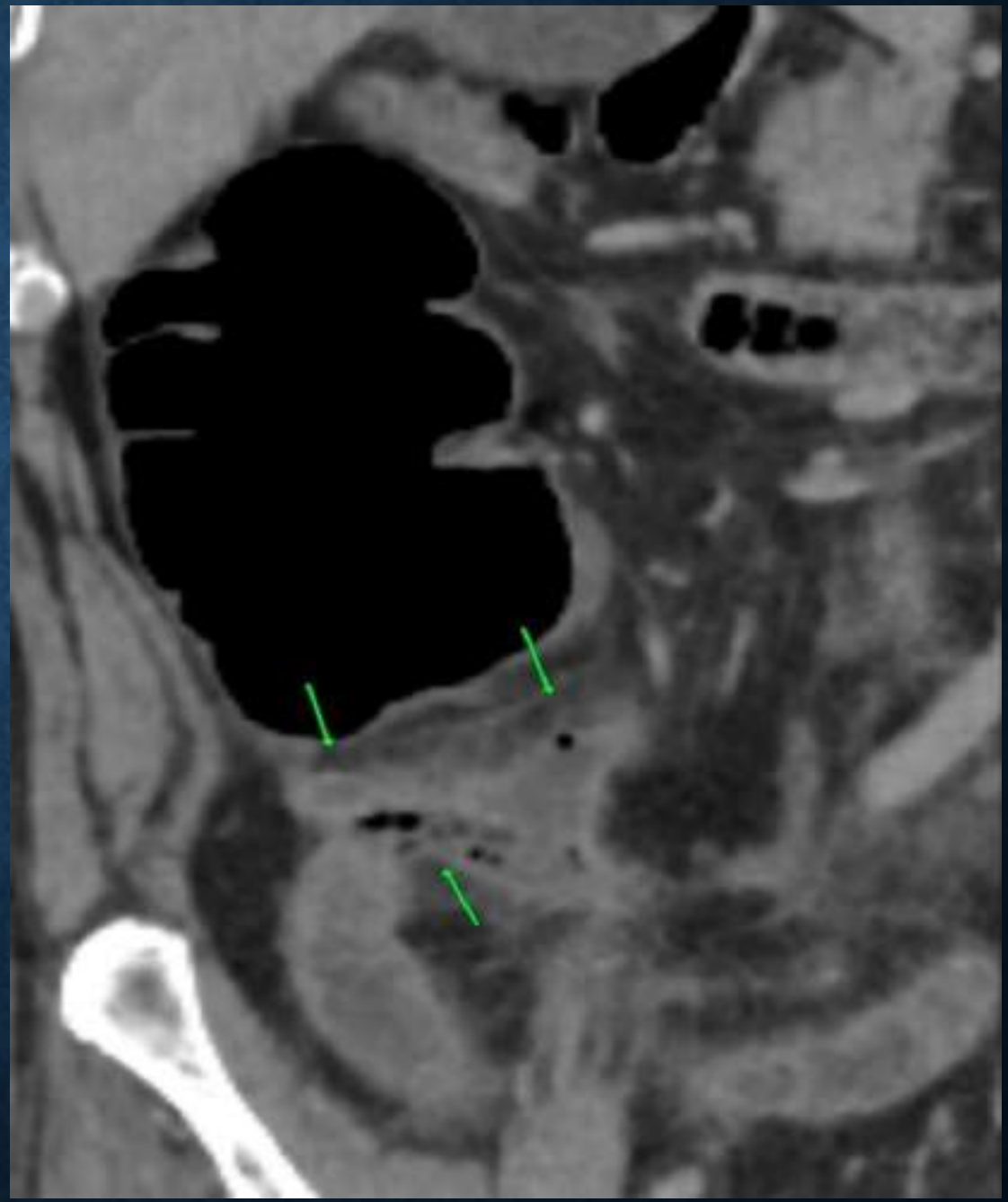

INVESTIGATIONS:

- CBC: 9/10/26

  Total count of WBC 13.48 x 10^9/ L

  Neutrophil 85%

  Hb% 10.9 g/dl

  Hematocrit 33.5%

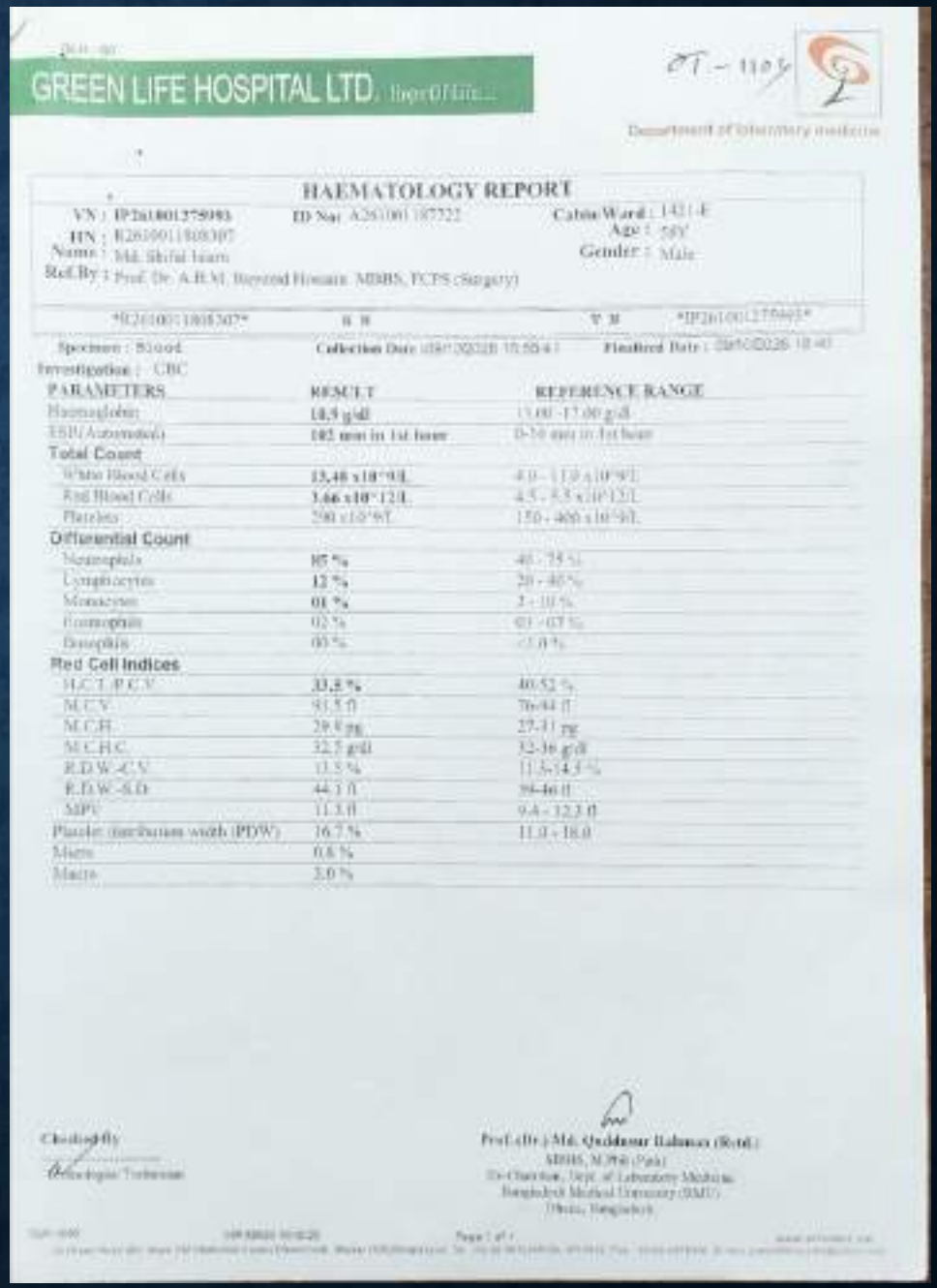

GREEN LIFE HOSPITAL LTD.

HAEMATOLOGY REPORT

PARAMETERS	RESULT	REFERENCE RANGE
Haemoglobin	10.9 g/dl	13.00 -17.00 g/dl
ESR(Automated)	102 mm in 1st hour	0-10 mm in 1st hour
Total Count		
White Blood Cells	13.48 x10^9/L	4.0 - 11.0 x10^9/L
Red Blood Cells	3.66 x10^12/L	4.5 - 5.5 x10^12/L
Platelets	500 x10^9/L	150 - 400 x10^9/L
Differential Count		
Neutrophils	85 %	40 - 75 %
Lymphocytes	12 %	20 - 40 %
Monocytes	01 %	2 - 10 %
Eosinophils	02 %	01 - 07 %
Basophils	00 %	<1.0 %
Red Cell Indices		
H.C.T./P.C.V.	33.5 %	40-52 %
M.C.V.	91.5 fl	76-94 fl
M.C.H.	29.8 pg	27-31 pg
M.C.H.C.	32.5 g/dl	32-36 g/dl
R.D.W.-C.V.	13.5 %	11.5-14.5 %
R.D.W.-S.D.	44.1 fl	39-46 fl
MPV	11.3 fl	9.4 - 12.3 fl
Platelet distribution width (PDW)	16.7 %	11.0 - 18.0
Myelo	0.8 %	
Macro	3.0 %	

Prof.(Dr.) Md. Quddusur Rahman (Retd.)

INVESTIGATIONS:

- S. Electrolyte: 09/10/26

Parameter	Result
S. Electrolytes	
Sodium	**134 mmol/L**
Potassium	**3.0 mmol/L**
Chloride	99 mmol/L
T-CO2(Venous)	27.5 mmol/L
S. Magnesium	2.1 mg/dL
S. Albumin	**24 gm/L**
S. Calcium	**8.0 mg/dl**
S.Creatinine	1.1 mg/dl

INVESTIGATIONS:

Chest X-ray P/A View: 9/10/26

- Chest: Normal
- Abdomen: Distended bowel loops



Confirmatory Diagnosis: **Appendicular abscess**

MANAGEMENT:

- Plan of treatment :

  Exploratory Laparotomy

  by Midline incision under

  General Anesthesia on

  9/10/26 at 6:30pm.



LAPAROTOMY:

- At laparotomy , we found

  - dilated intestinal loops

  - ascites

  - lump in the right iliac fossa covered by omentum.



LAPAROTOMY:

- After removing the omentum, huge pus collection was found.

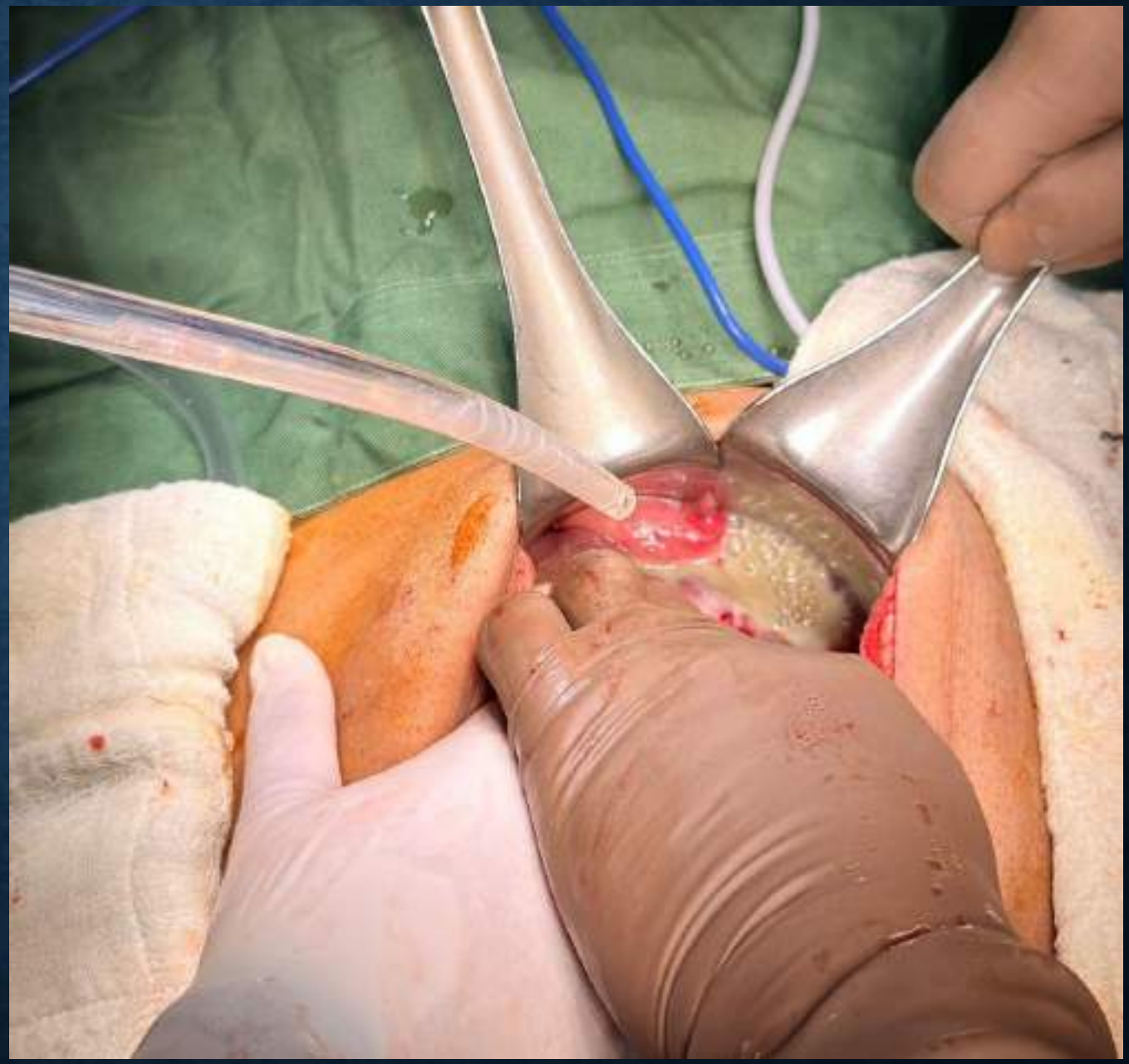

LAPAROTOMY:

- Appendix was found gangrenous, retro-caecal, perforated at the base with feacolith inside.





LAPAROTOMY:

- Appendicectomy was done by ligating base with 1-0 vicryl.







LAPAROTOMY:

- Enterotomy was done to decompress the distended intestinal loops.

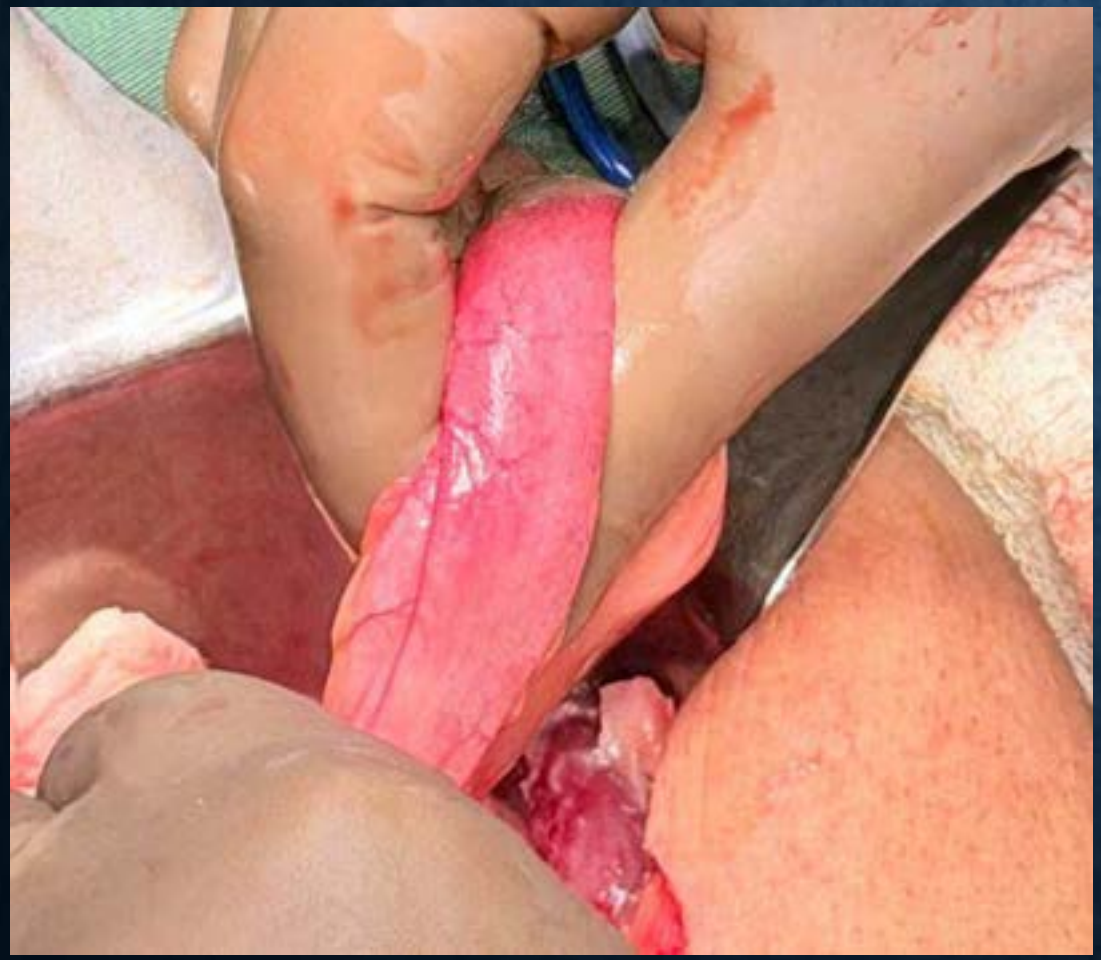

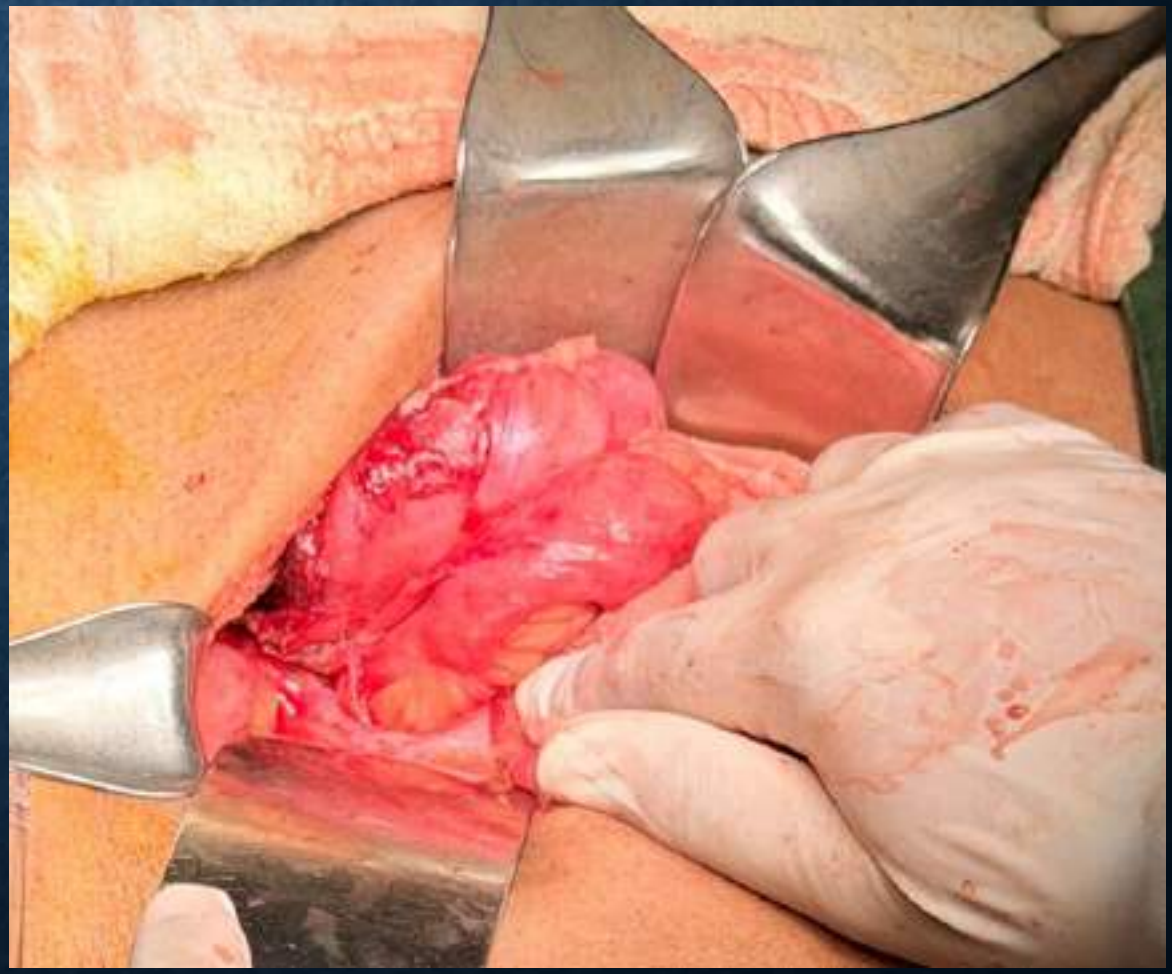

LAPAROTOMY:

- Peritoneal toileting was done with normal saline mixed with povidone iodine.
- A Drain tube was placed in the pelvic cavity
- Abdomen was closed in layers.
- Pus was sent for C/S and resected Appendix was sent for histopathology.

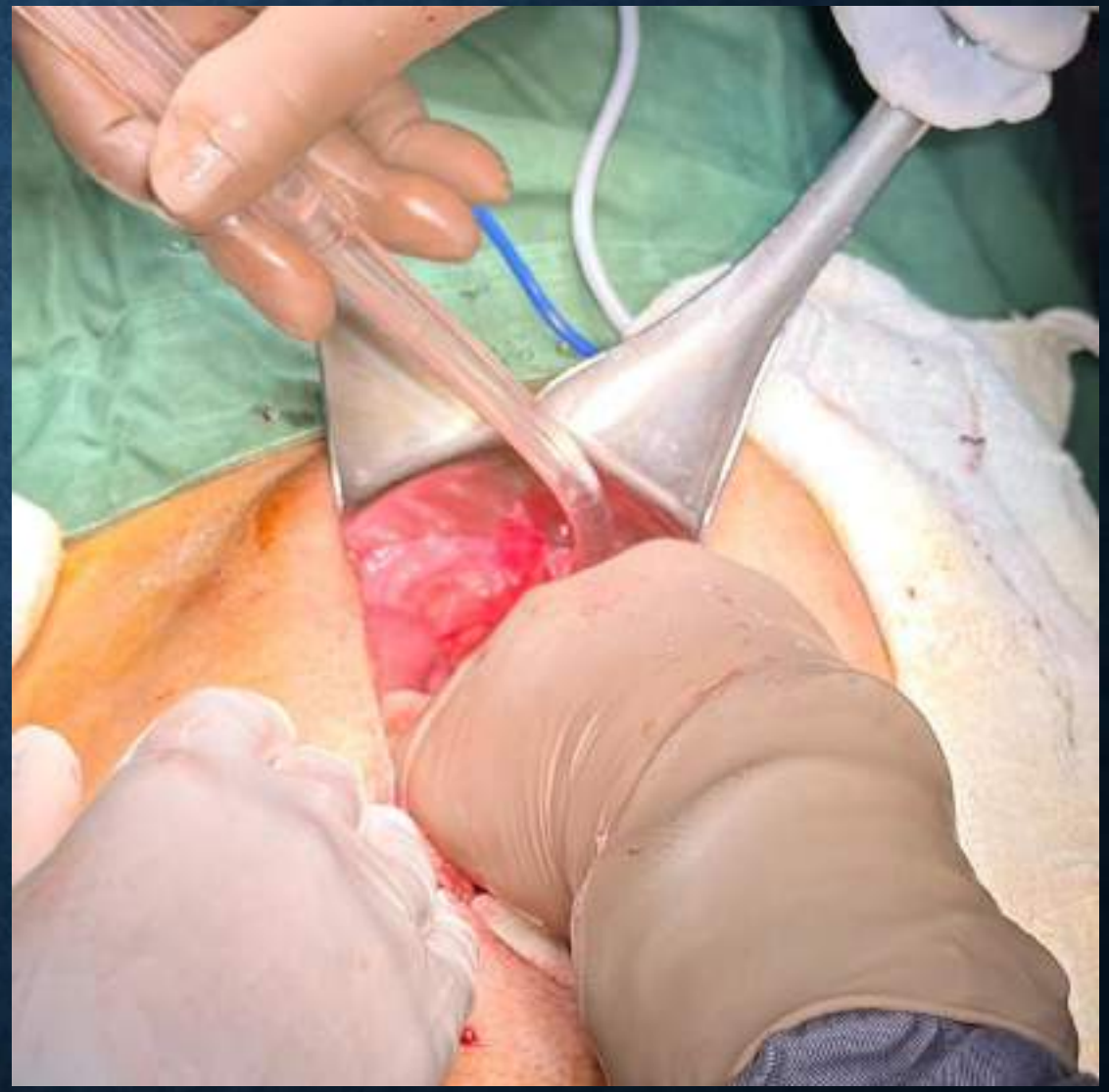

- Pus C/S: Esch. Coli
- Histopathology: Acute diffuse suppurative appendicitis with peritonitis

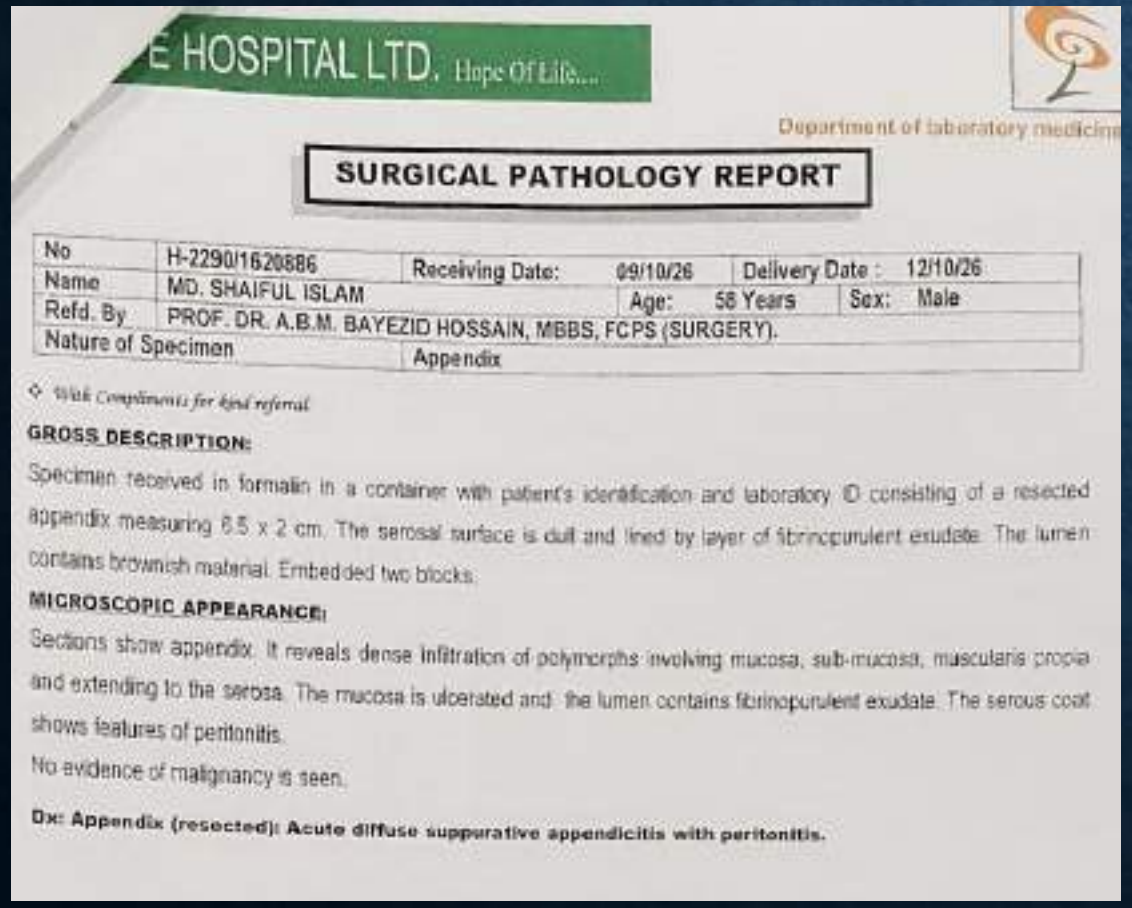

E HOSPITAL LTD. Hope Of Life....

Department of laboratory medicine

SURGICAL PATHOLOGY REPORT

No	H-2290/1620886	Receiving Date:	09/10/26	Delivery Date :	12/10/26
Name	MD. SHAIFUL ISLAM		Age: 58 Years	Sex:	Male
Refd. By	PROF. DR. A.B.M. BAYEZID HOSSAIN, MBBS, FCPS (SURGERY).				
Nature of Specimen	Appendix				

With Compliments for kind referral

GROSS DESCRIPTION:

Specimen received in formalin in a container with patient's identification and laboratory ID consisting of a resected appendix measuring 6.5 x 2 cm. The serosal surface is dull and lined by layer of fibrinopurulent exudate. The lumen contains brownish material. Embedded two blocks.

MICROSCOPIC APPEARANCE:

Sections show appendix. It reveals dense infiltration of polymorphs involving mucosa, sub-mucosa, muscularis propia and extending to the serosa. The mucosa is ulcerated and the lumen contains fibrinopurulent exudate. The serous coat shows features of peritonitis.

No evidence of malignancy is seen.

Dx: Appendix (resected): Acute diffuse suppurative appendicitis with peritonitis.

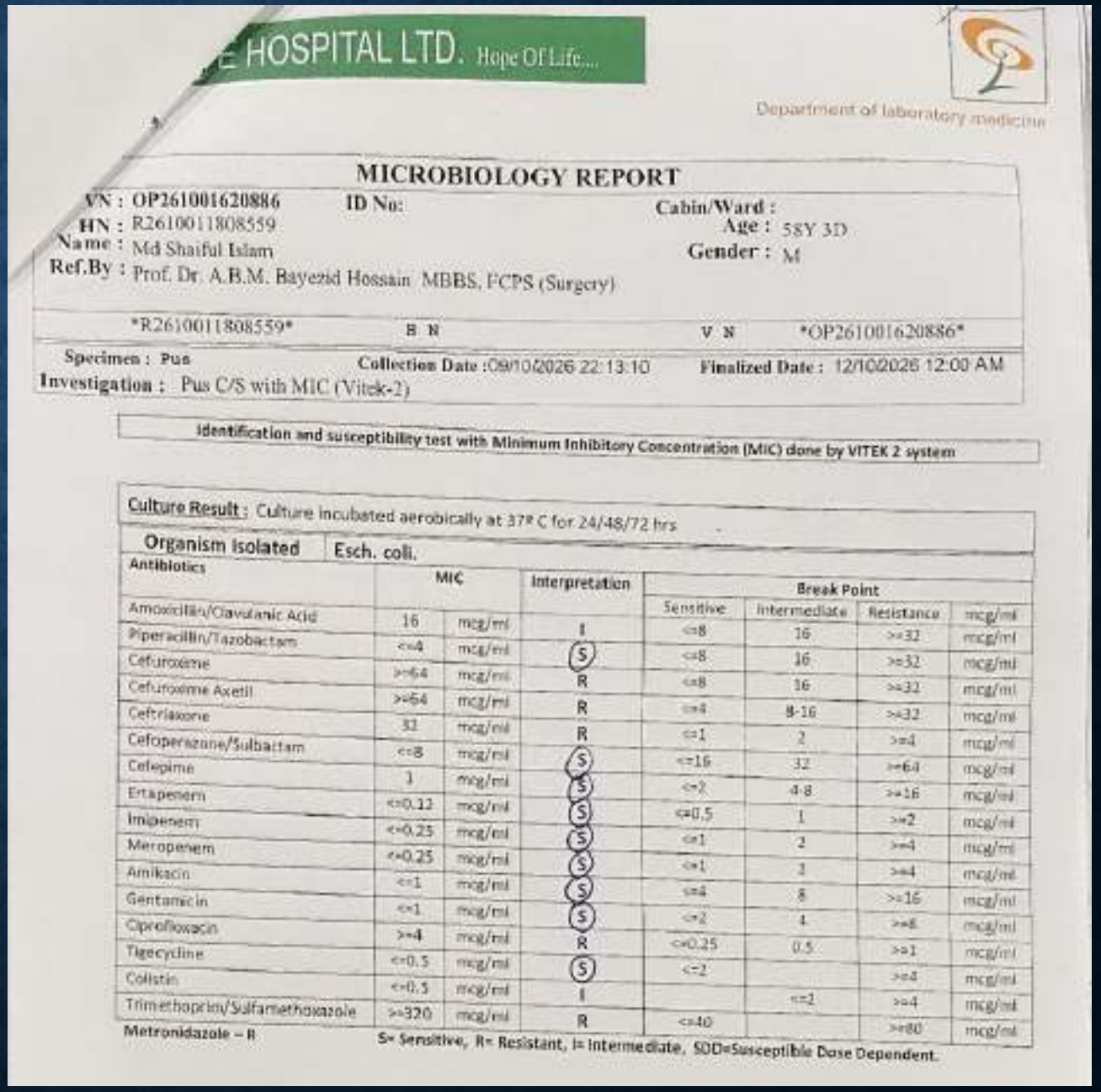

E HOSPITAL LTD. Hope Of Life....

Department of laboratory medicine

MICROBIOLOGY REPORT

VN : OP2610016208886 ID No: Cabin/Ward :
HN : R2610011808559 Age : 58Y 3D
Name : Md Shaiful Islam Gender : M
Ref.By : Prof. Dr. A.B.M. Bayezid Hossain MBBS, FCPS (Surgery)

R2610011808559 B N V N *OP2610016208886*

Specimen : Pus Collection Date :09/10/2026 22:13:10 Finalized Date : 12/10/2026 12:00 AM
Investigation : Pus C/S with MIC (Vitek-2)

Identification and susceptibility test with Minimum Inhibitory Concentration (MIC) done by VITEK 2 system

Culture Result : Culture incubated aerobically at 37° C for 24/48/72 hrs

Organism Isolated : Esch. coli.

Antibiotics	MIC		Interpretation	Break Point			
				Sensitive	Intermediate	Resistance	
Amoxicillin/Clavulanic Acid	16	mcg/ml	I	<=8	16	>=32	mcg/ml
Piperacillin/Tazobactam	<=4	mcg/ml	S	<=8	16	>=32	mcg/ml
Cefuroxime	>=64	mcg/ml	R	<=8	16	>=32	mcg/ml
Cefuroxime Axetil	>=64	mcg/ml	R	<=4	8-16	>=32	mcg/ml
Ceftriaxone	32	mcg/ml	R	<=1	2	>=4	mcg/ml
Cefoperazone/Sulbactam	<=8	mcg/ml	S	<=16	32	>=64	mcg/ml
Cefepime	1	mcg/ml	S	<=2	4-8	>=16	mcg/ml
Ertapenem	<=0.12	mcg/ml	S	<=0.5	1	>=2	mcg/ml
Imipenem	<=0.25	mcg/ml	S	<=1	2	>=4	mcg/ml
Meropenem	<=0.25	mcg/ml	S	<=1	2	>=4	mcg/ml
Amikacin	<=1	mcg/ml	S	<=4	8	>=16	mcg/ml
Gentamicin	<=1	mcg/ml	S	<=2	4	>=8	mcg/ml
Ciprofloxacin	>=4	mcg/ml	R	<=0.25	0.5	>=1	mcg/ml
Tigecycline	<=0.5	mcg/ml	S	<=2		>=4	mcg/ml
Colistin	<=0.5	mcg/ml	I		<=2	>=4	mcg/ml
Trimethoprim/Sulfamethoxazole	>=320	mcg/ml	R	<=40		>=80	mcg/ml

Metronidazole – R

S= Sensitive, R= Resistant, I= Intermediate, SDD=Susceptible Dose Dependent.

POST OPERATIVE PERIOD:

1ST POD: 10/10/26

- Uneventful.

S. Electrolytes	
Sodium	136 mmol/L
Potassium	**3.3 mmol/L**
Chloride	104 mmol/L
T-CO2(Venous)	27.6 mmol/L
S. Magnesium	1.9 mg/dL
S. Albumin	**20 gm/L**
S. Calcium	**7.0 mg/dl**
S.Creatinine	1.2 mg/dl

Investigation : CBC

PARAMETERS	RESULT
Haemoglobin	**9.9 g/dl**
ESR(Automated)	**121 mm in 1st hour**
Total Count	
White Blood Cells	**17.17 x10^9/L**
Red Blood Cells	**3.34 x10^12/L**
Platelets	249 x10^9/L
Differential Count	
Neutrophils	**93 %**
Lymphocytes	**04 %**
Monocytes	03 %
Eosinophils	**00 %**
Basophils	00 %
Red Cell Indices	
H.C.T./P.C.V.	**29.7 %**
M.C.V	88.9 fl
M.C.H.	29.6 pg
M.C.H.C.	33.3 g/dl
R.D.W.-C.V.	14.2 %
R.D.W.-S.D.	45.8 fl
MPV	12.0 fl
Platelet distribution width (PDW)	14.8 %
Micro	1.8 %
Macro	3.2 %

3TH POD: 12/10/26

- He developed severe respiratory distress for 1 hour.
- Patient was shifted to ICU at 1:30 am.
- Portable X-ray Chest A/P view done at 2:17 am which showing diffuse bilateral pulmonary edema.
- He was treated accordingly at ICU
- Shifted to cabin on 4th POD on 13/10/26 at 11:43 am.



6TH POD: 15/10/26

- He developed abdominal distension & bowel sound was absent suggestive of intestinal obstruction with clinical suspicion of impending burst abdomen.
- A Contrast enhanced CT scan of Chest and Whole abdomen was done.

Contrast enhanced CT scan of whole abdomen:

6th POD (15/10/26)

- Multiple dilatation of small and large bowel loops with air fluid levels

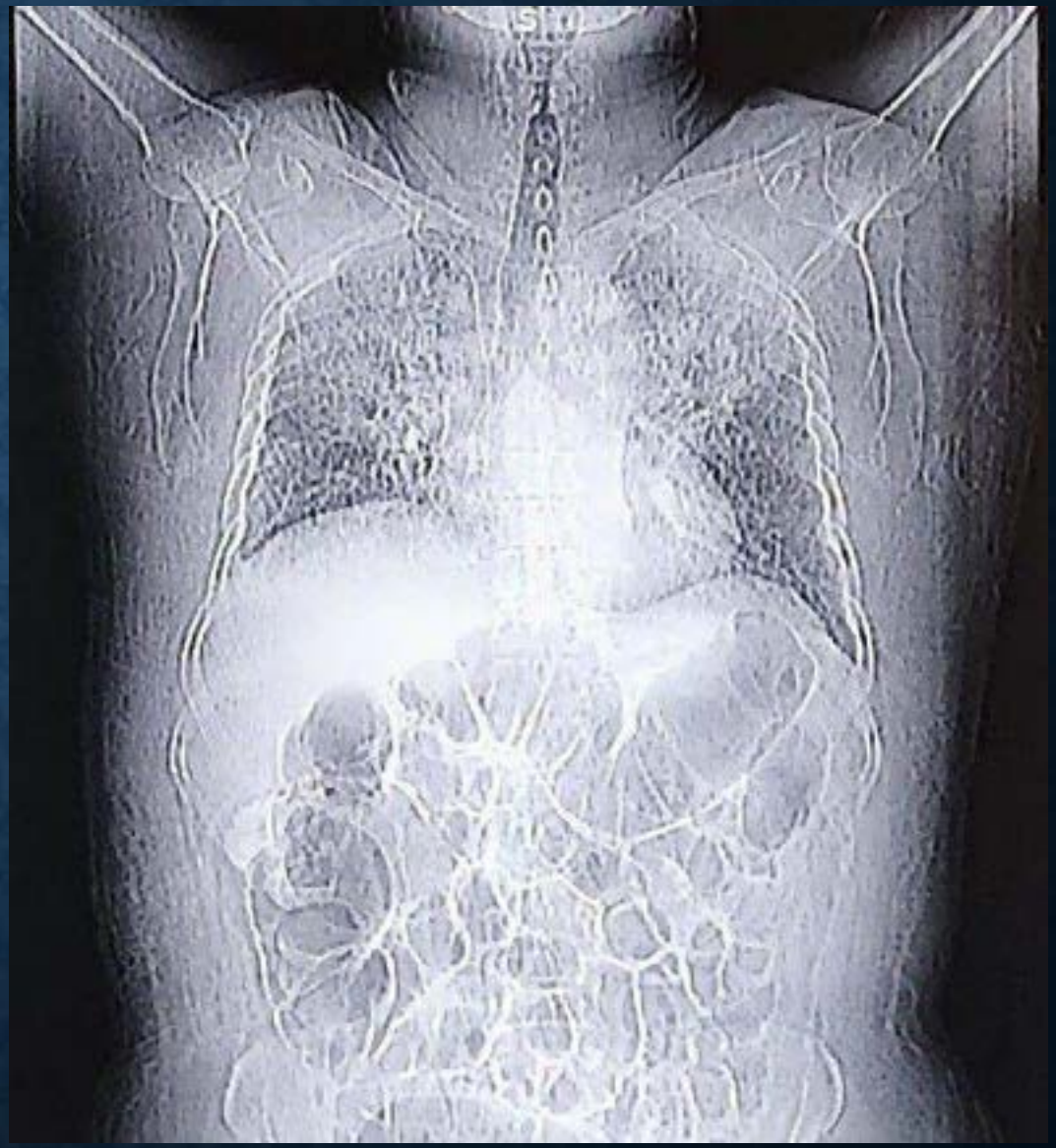

Contrast enhanced CT scan of whole abdomen:

6th POD (15/10/26)

- Showed Feature of Impending burst abdomen.

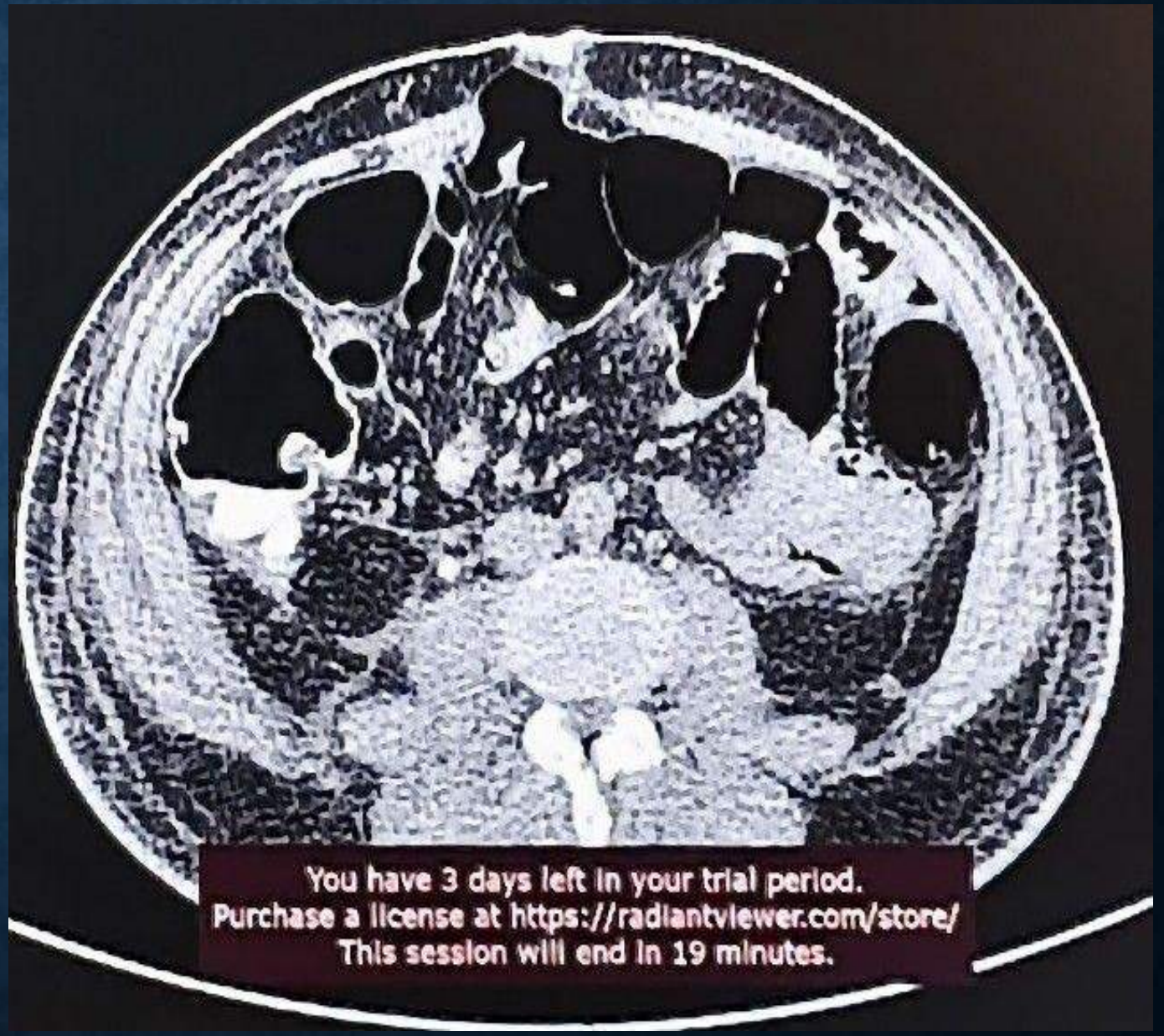

Contrast enhanced CT scan of Chest:

6th POD (15/10/26)

- Bilateral moderate pleural effusion
- Bilateral pulmonary edema
- Multiple consolidations at both lungs.
- Cardiomegaly with mild pericardial effusion





Sputum for C/S:

Pseudomonas spp.

8TH POD: 17/10/26

- Patient developed burst abdomen.
- Plan of treatment: Secondary closure under General Anaesthesia .



SECONDARY CLOSURE: 8TH POD

- All previous stiches were removed
- Upon opening the peritoneal cavity peritoneal fluid was sucked out.
- Whole peritoneal cavity was thoroughly checked . At previous enterotomy site epithelial erosion was present which was reinforced.
- A drain tube placed at pelvic cavity.
- Peritoneal cavity closed with continuous stiches by PDS and skin closed with tension suture.



4TH POD: 21/10/26

On 4th POD of Secondary closure,

- X-ray chest A/P view



DISCHARGE:

- At 8th POD patient was discharged after checking wound.
- He was in stable condition during discharge.
- Our plan is to remove all the stiches on 14th POD.

ADVICE DURING DISCHARGE:

- Not to do heavy work for at least 3 month.
- To use cotton abdomen binder for at least 6 month.
- Follow up after 1 month.
- To continue other medication.

TAKE HOME MESSAGE

- Now a days, many of the clinicians focus on investigation reports rather than spending adequate time taking a detailed history and performing a thorough clinical examination. As a result, we often miss important historical details and obvious clinical findings, that leads to delay in the diagnosis at the right time and leading to the development of multiple complications that increase morbidity of the patients as well as mortality.
- All these consequences could be avoided if a detailed history were taken and a meticulous clinical examination were performed in time.


THANK
YOU