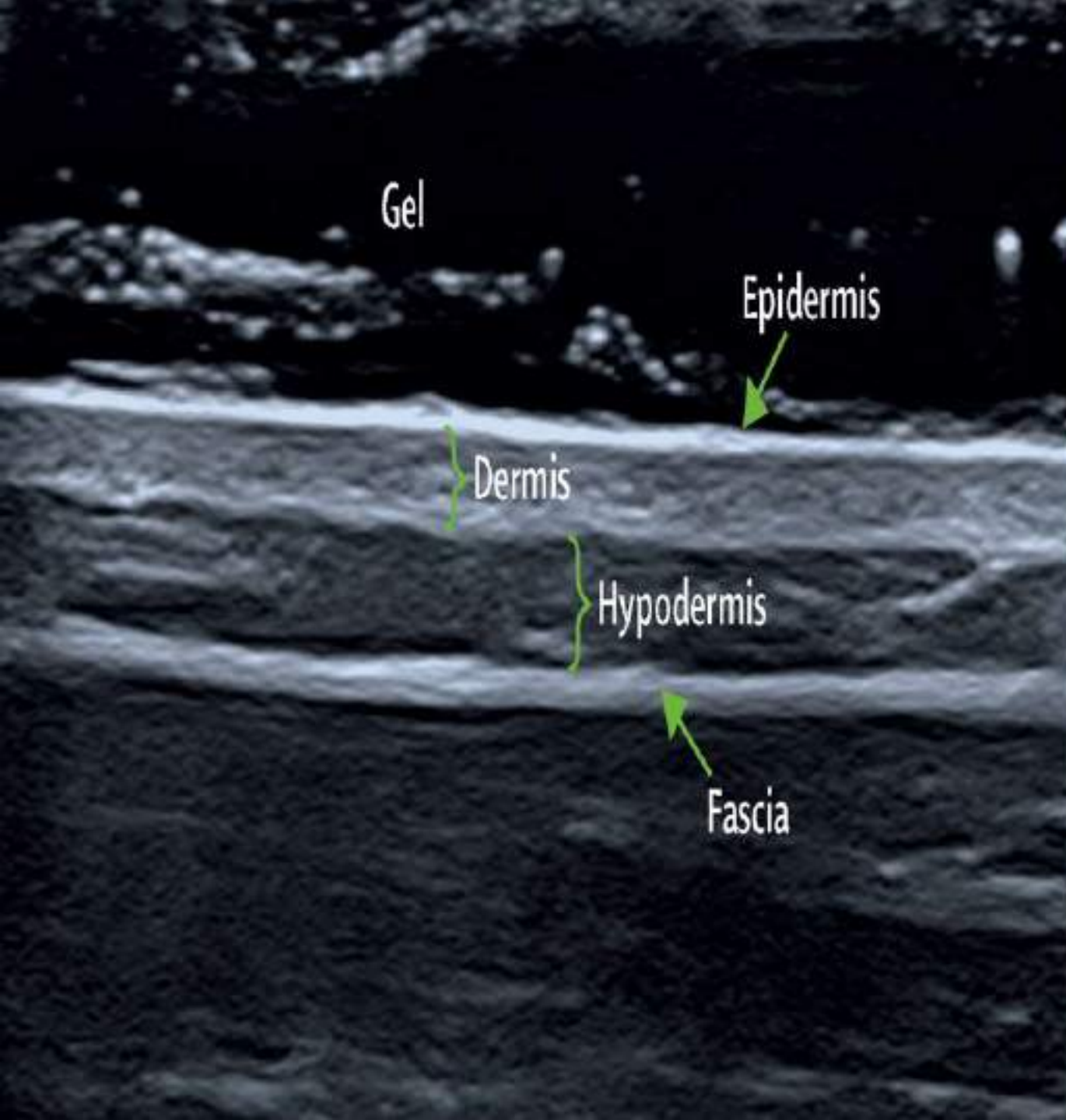

Skin Ultrasound in Rheumatology: Seeing the Invisible

Dr A T M Tanveer Hasan (MBBS, MD)
Associate Professor of Rheumatology

Green Life Medical College
Member of the OMERACT
Skin Ultrasound Subgroup

What Drove Me to Choose the Topic

- Ultrasound is the only imaging modality for seeing through the skin real-time without radiation hazards
- Getting the audience introduced to '**Rheumatological Ultrasound**' (which is not just MSK ultrasound!)

Abstract N°: 2806
Track: B) Clinical research
Topic: Across diseases
Sub-Topic: Adult Rheumatology
Keywords: Skin , Ultrasound , Validation

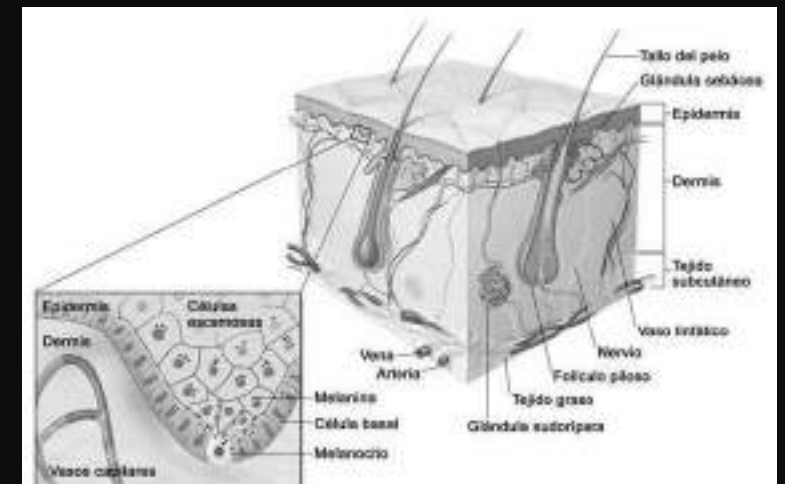
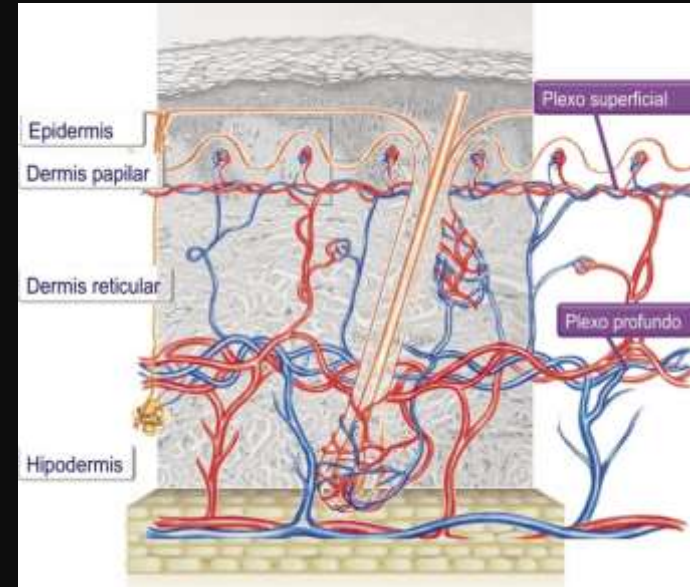
**Assessment of skin with high-frequency ultrasound: results from a Delphi process by the OMERACT
Ultrasound Working group**

Peter Mandl¹, Luis Coronel², Clara Watschinger¹, Andrea Delle Sedie³, Valentina Dini³, Annamaria Iagnocco⁴, Georgios Filippou⁵, Emilio Filippucci⁶, **A T M Tanveer Hasan**⁷, Cristina Hernandez-Diaz⁸, Helen Keen⁹, Bushra Khanjar¹⁰, Kok Ooi Kong¹¹, Anna Lopez-Ferrer¹², Mihaela Micu¹³, Esperanza Naredo¹⁴, Carlos Pineda¹⁵, Francesco Porta¹⁶, Chiara Rizzo¹⁷, Tânia Santiago¹⁸, Pedro Santos-Moreno¹⁹, Russka Shumnalieva²⁰, Silvia Sirotti⁵, Lene Terslev²⁵, PLAMEN TODOROV²⁶, Esther Vicente-Rabaneda²¹, Ximenia Wortsman²², Maria-Antonietta D'Agostino²³, Ingrid Möller²⁴
on behalf of OMERACT Ultrasound Working Group

Issues to be Discussed

- ❖ Basics of skin ultrasound
- ❖ Scope of skin ultrasound in psoriasis
- ❖ Scope of nail ultrasound in psoriatic arthritis
- ❖ Other applications of skin ultrasound in rheumatology
- ❖ Take-home messages

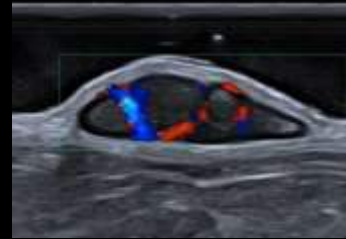
- The skin comprises two layers, the epidermis and dermis, although subcutaneous tissue can be considered a third layer.
- Evaluation of the skin and annexes and its pathologic conditions can sometimes be complex with only physical or dermatologic examination.



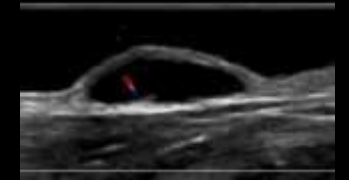
Technique	View/Section	Depth of Penetration	Visualized Structures
Dermoscopy	Horizontal	-	Superficial vascular pattern
			Scale distribution
			Plaque background color
High-frequency ultrasound (20–100 MHz)	Vertical	1–12 mm	Epidermis and dermis
Reflectance confocal microscopy	Horizontal	200–300 μ m	Epidermis and superficial dermis
Optical coherence tomography	Horizontal/Vertical	1–2 mm	Epidermis and superficial dermis
Optical microangiography—an extension of OCT	Vertical/3D	2 mm	Microcirculatory tissue beds
Laser Doppler imaging	Horizontal	2 mm	Cutaneous blood flow
Multiphoton tomography—subcellular resolution	Horizontal/Vertical	200–250 μ m	Epidermis and superficial dermi

The minimum
transducer
frequency for skin
US should be 15
MHz

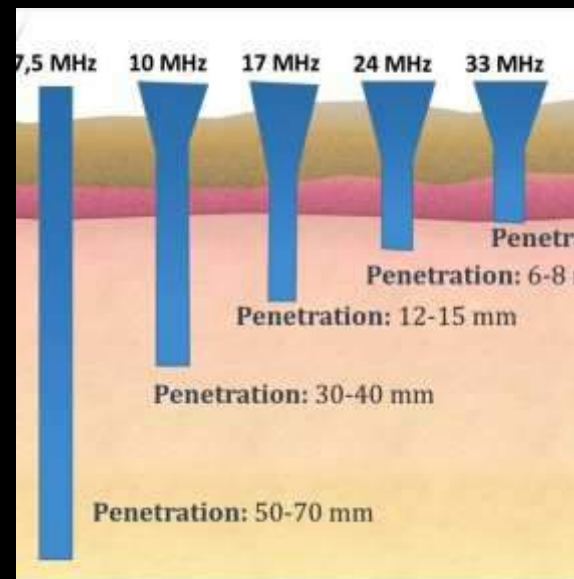
RSNA 2020 Annual Meeting
for *RadioGraphics* Fundamentals.

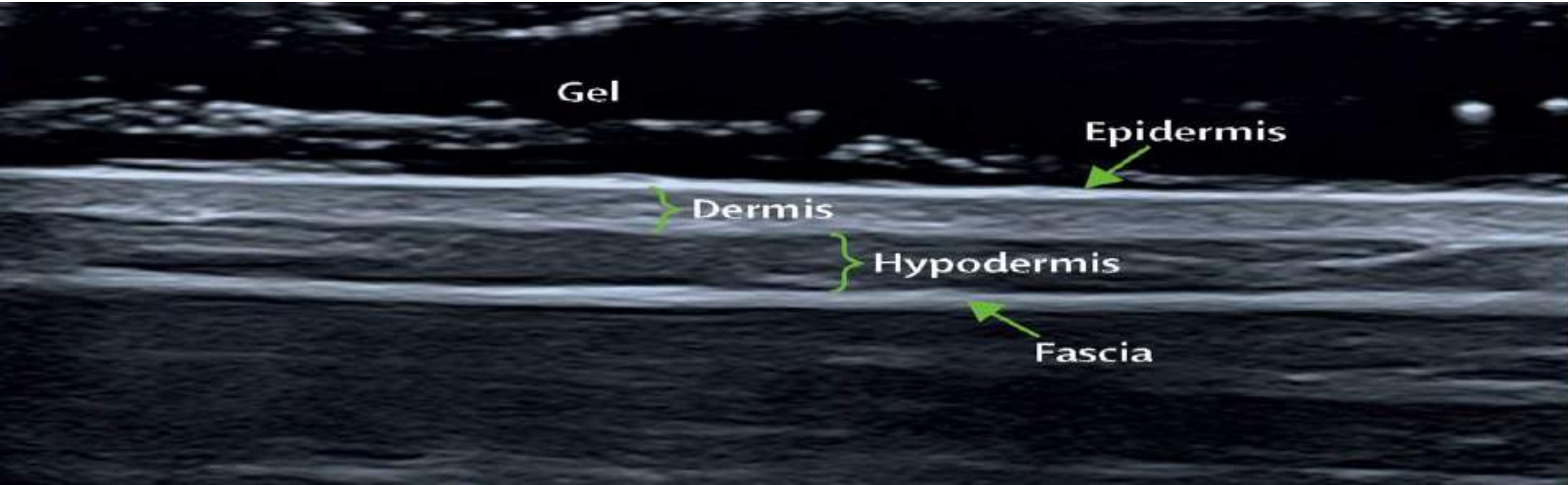


24MHz



14MHz





✓ Epidermis thickness 0.06-0.6 mm

✓ Dermis thickness 1.0-4 mm

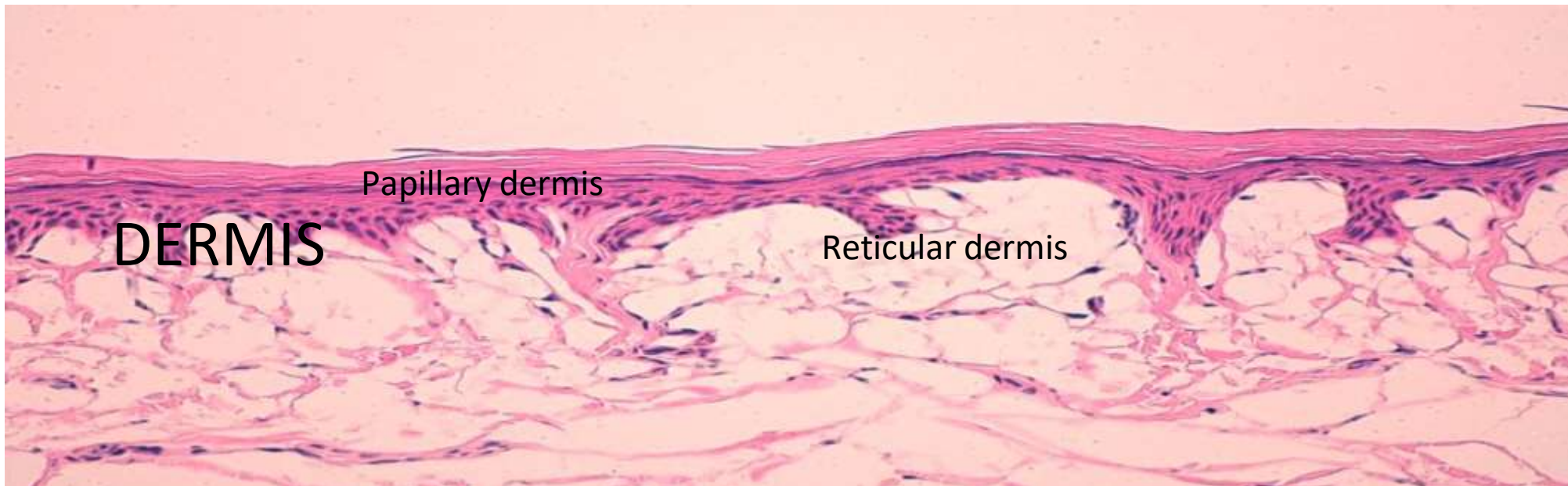
✓ Hypodermis thickness 5-20 mm

Epidermis

- ✓ Appears as a hyperechoic band

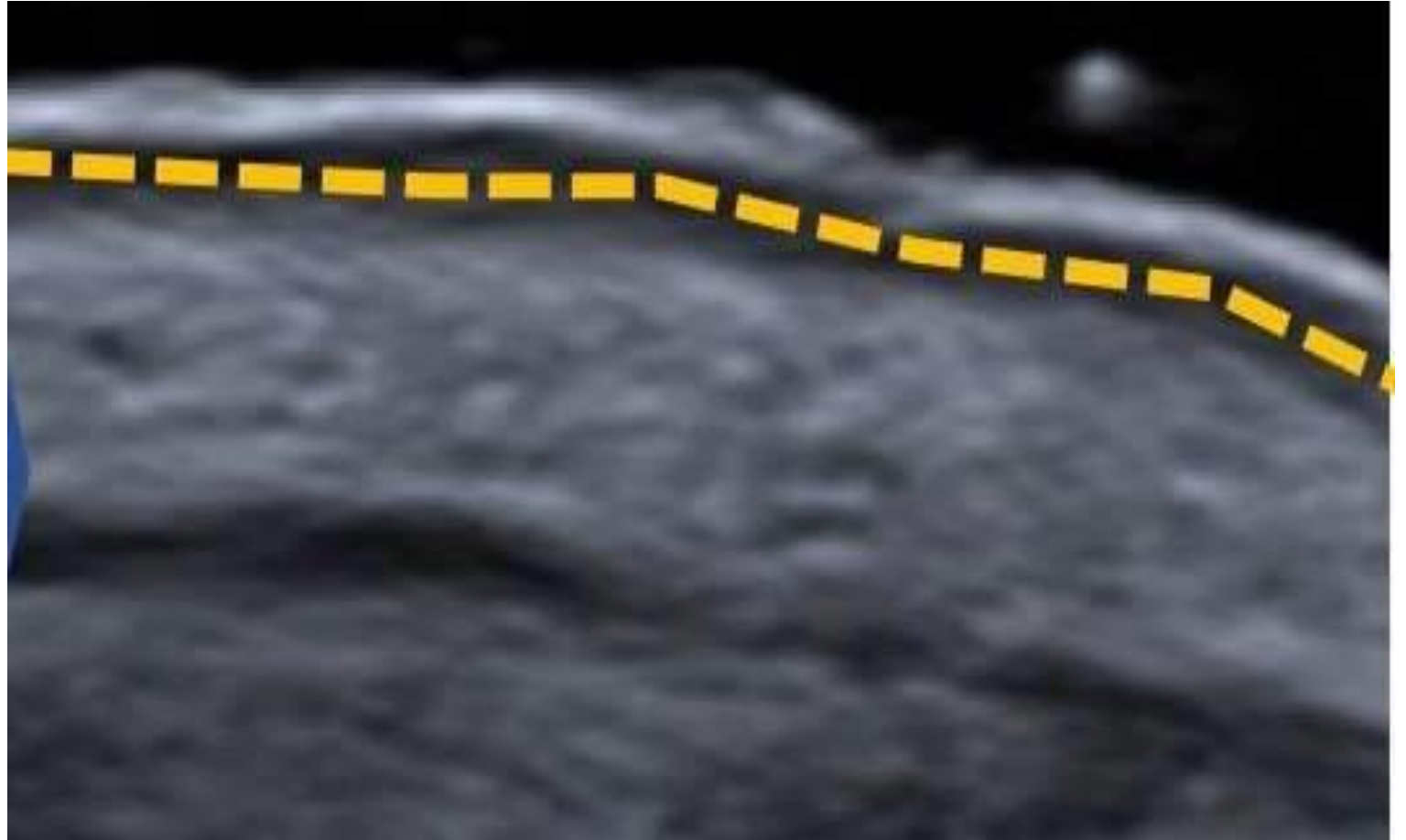
Dermis

- ✓ Less echogenic than the epidermis
- ✓ Although the two dermis layers, papillary and reticular, are different in composition and organization of the collagen fibers (the papillary dermis is more loosely packed), they are tough to differentiate by the US



What is SLEB?

The subepidermal low-echogenicity band (SLEB) is a sonographic sign of sun exposure or photoaging elastosis and corresponds to the lax papillary dermis

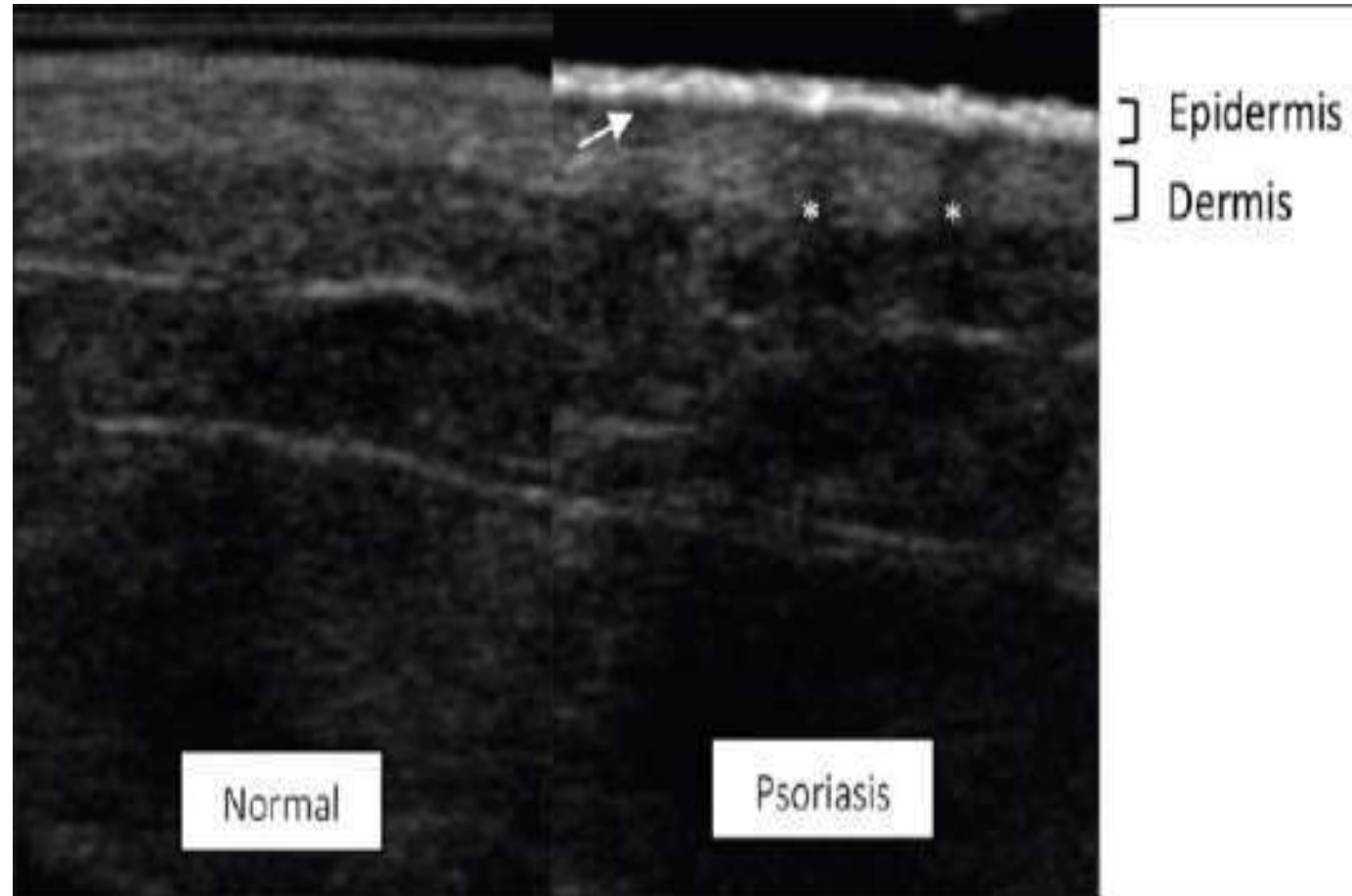


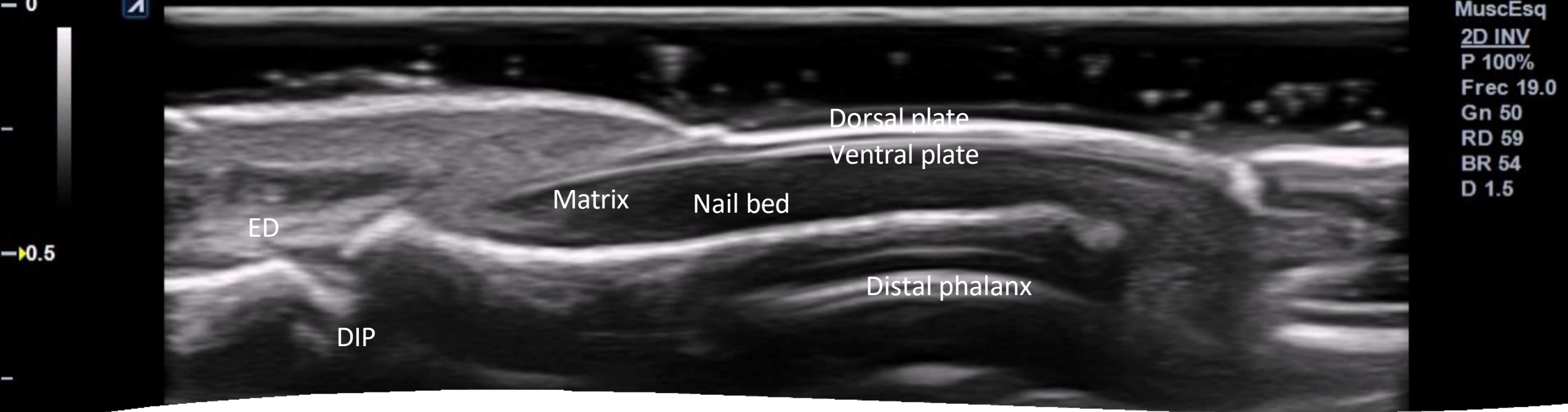
Particularly found in face, neck and the dorsum of the forearm

Mimic of SLEB

SLEB should not be confused with the hypoechoic band (corresponding to oedema and vasodilatation) in the upper (papillary) dermis encountered in inflammatory conditions, e.g.,

- ✓ Psoriasis
- ✓ Contact dermatitis
- ✓ Atopic dermatitis
- ✓ Acanthoma

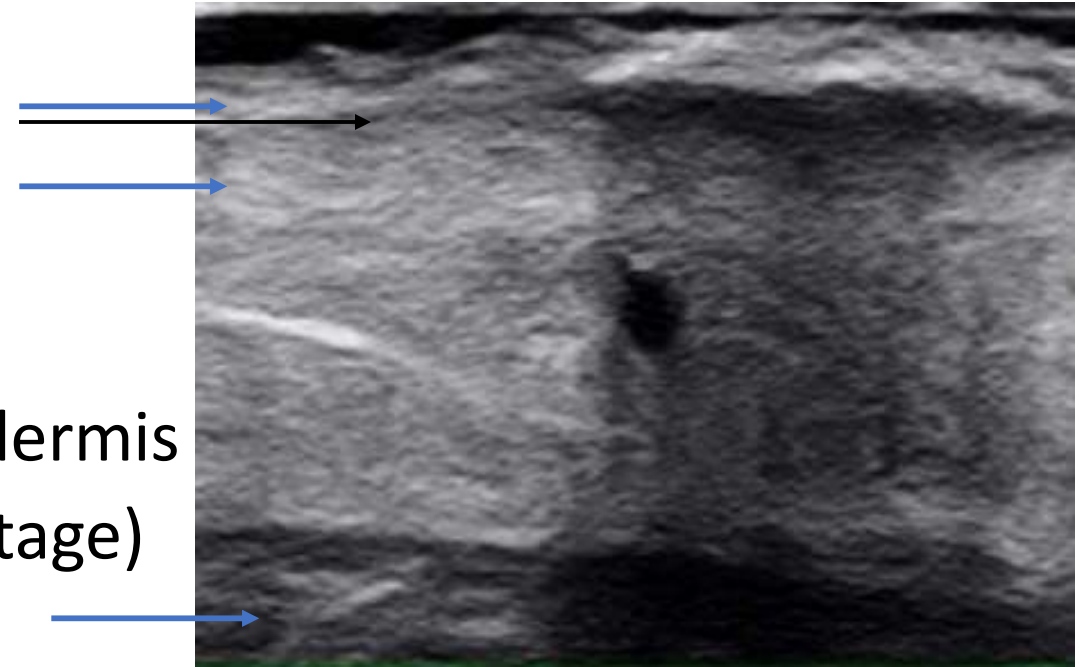




- ✓ Hyperechoic ventral and dorsal nail plates
- ✓ Anechoic interplate space
- ✓ Hypoechoic nail bed
- ✓ Isoechoic nail matrix at the proximal aspect of the nail bed

Sonographic Features of Skin Psoriasis

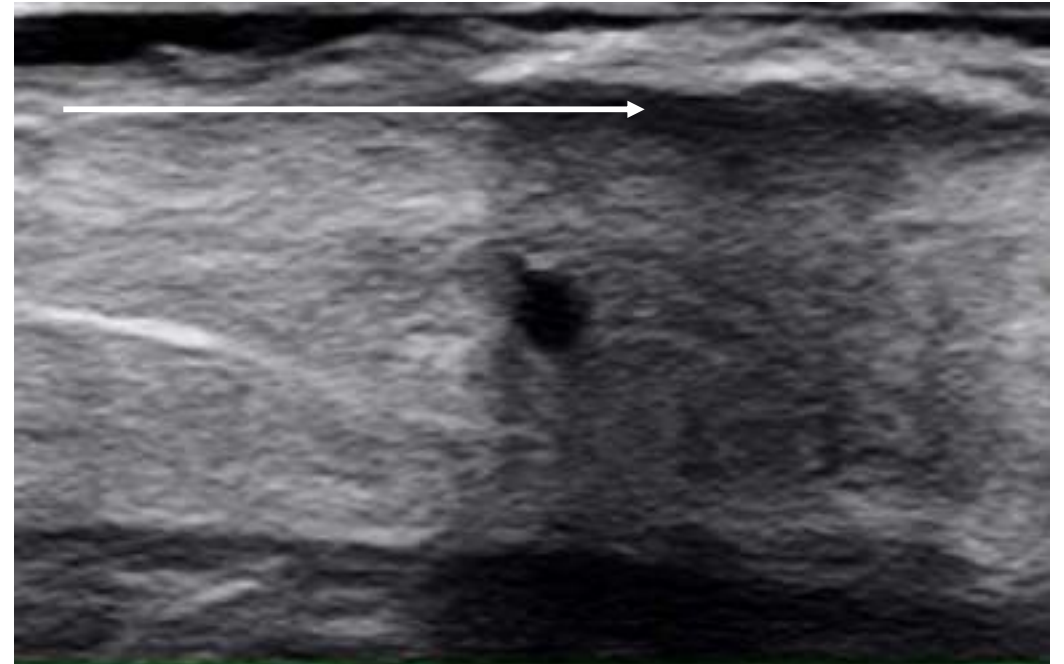- ✓ Thickening of epidermis
- ✓ Thickening of dermis
- ✓ Hypoechoic band in upper (papillary) dermis (indicative of the most active disease stage)
- ✓ Absence of the involvement of subcutaneous tissue
- ✓ Increased blood flow detected on power Doppler ultrasound



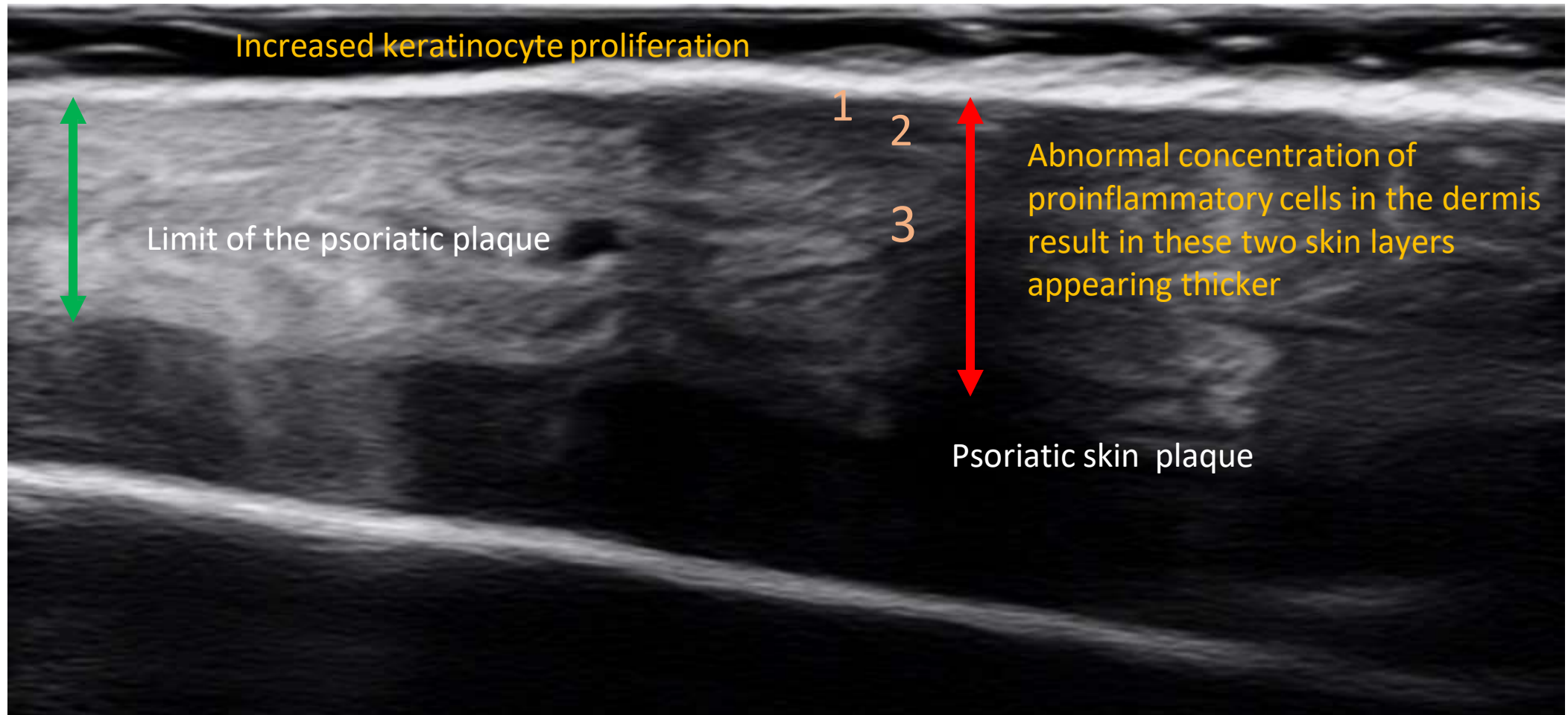
Sonographic Features of Skin Psoriasis (Contd.)

- ✓ When marked thickening of the epidermis occurs there may be seen a posterior acoustic shadowing artifact, that impedes a clear assessment of the underlying dermis

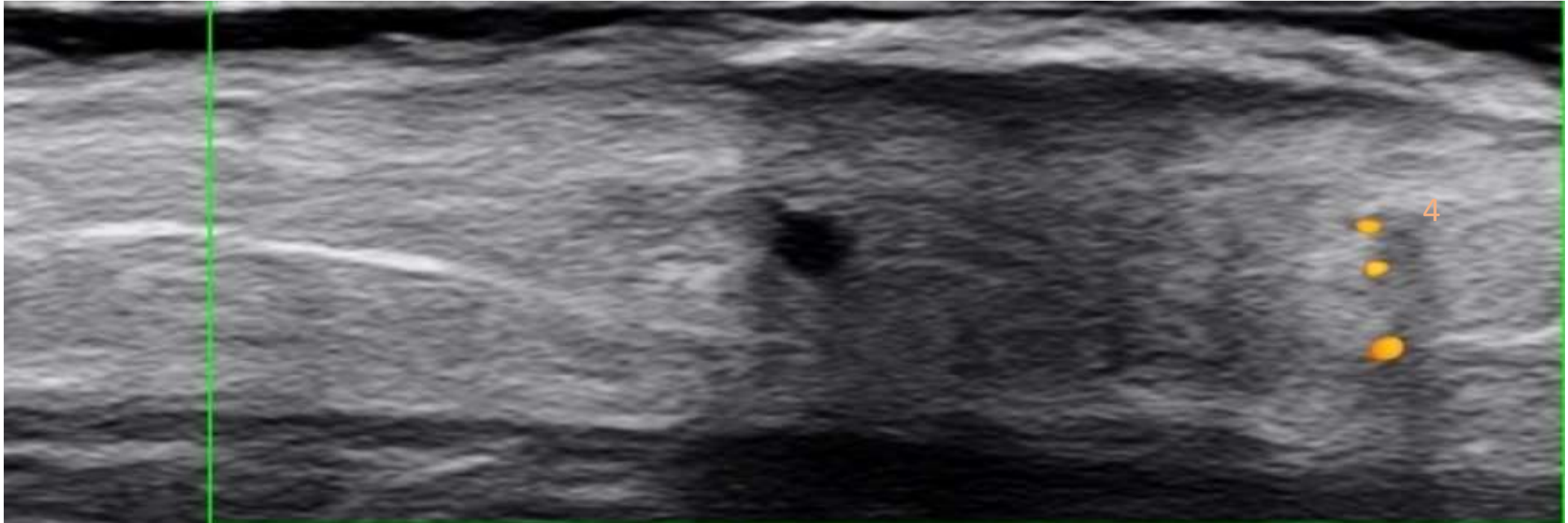Gutierrez M, Wortsman X, Filippucci E, De Angelis R, Filosa G, Grassi W.
2009 Nov;28(11):1569-74.



HOW DO WE MEASURE THE SKIN THICKNESS?

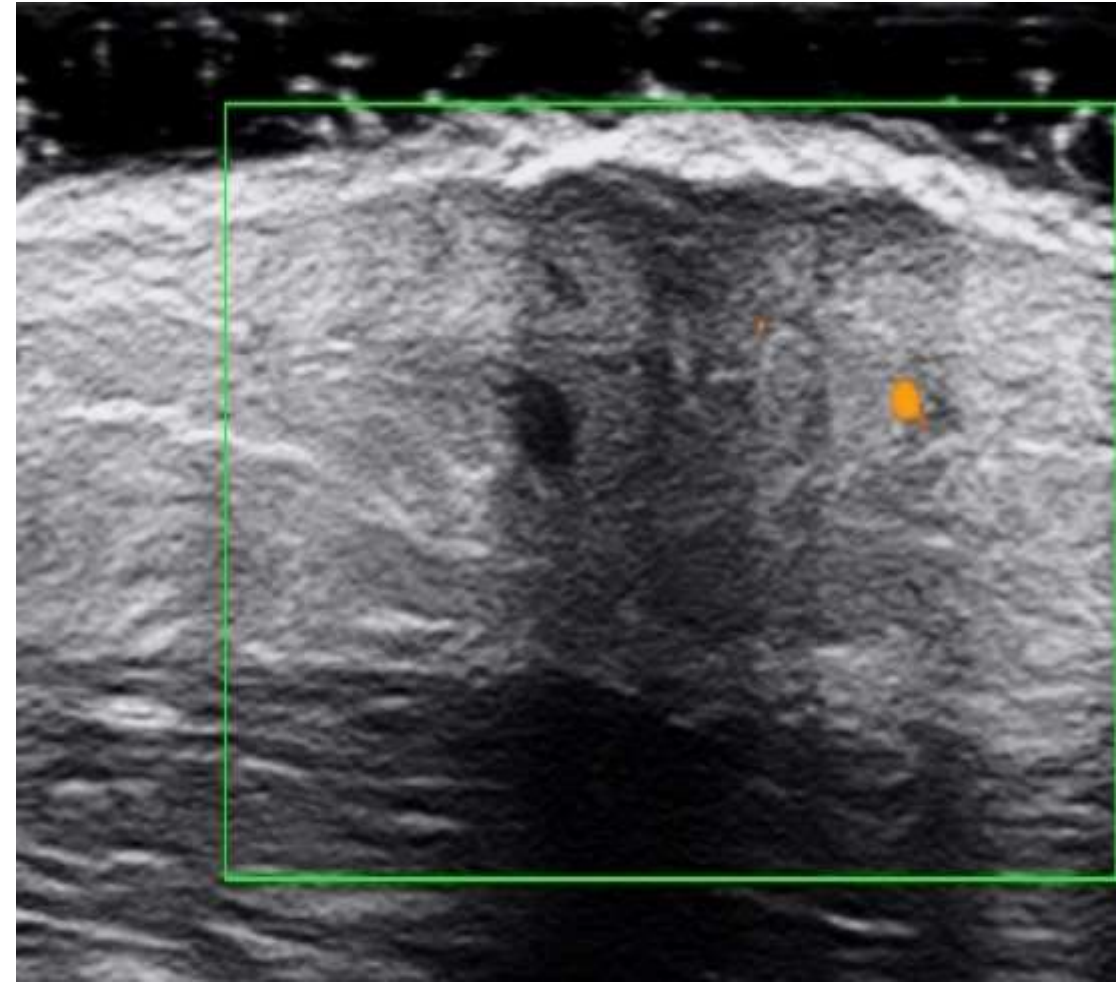
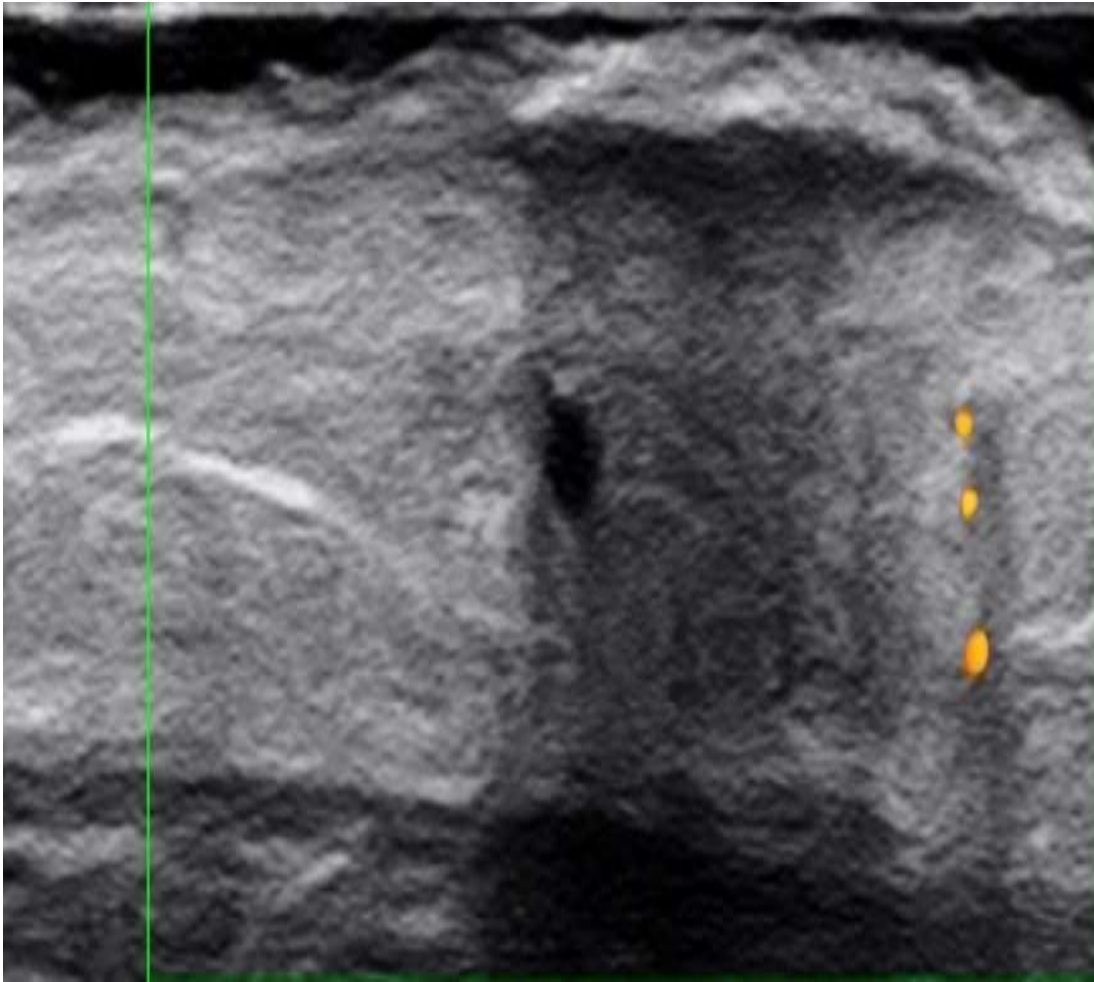


HOW DO WE MEASURE THE SKIN THICKNESS?



Normal thickness of the skin is widely variable according to the anatomic area, it is rational to perform an ultrasound comparison between the psoriatic plaque and the normal surrounding skin in the same area of the same patient.

Application in Clinical Practice: Objective Monitoring



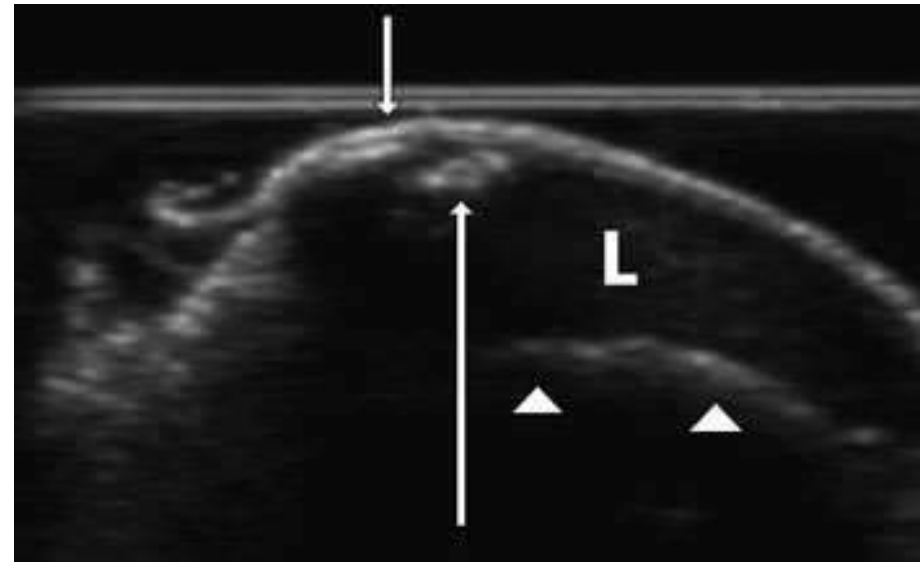
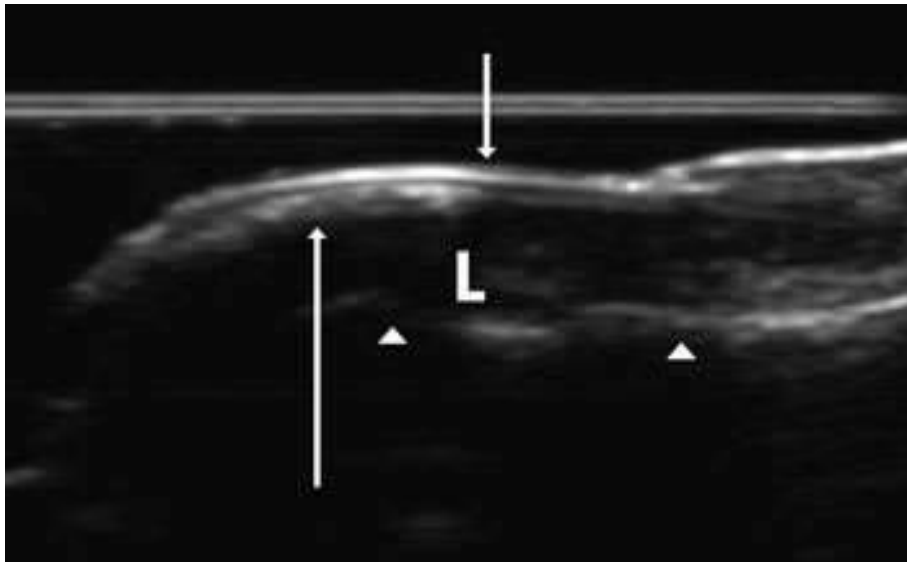
The reduction of epidermal and dermal thicknesses and principally the disappearance of the hypoechoic band at the upper dermis have been described as the main gray scale sonographic indicators of effective therapy

Wortsman Classification of Ultrasound Findings of Nail Psoriasis

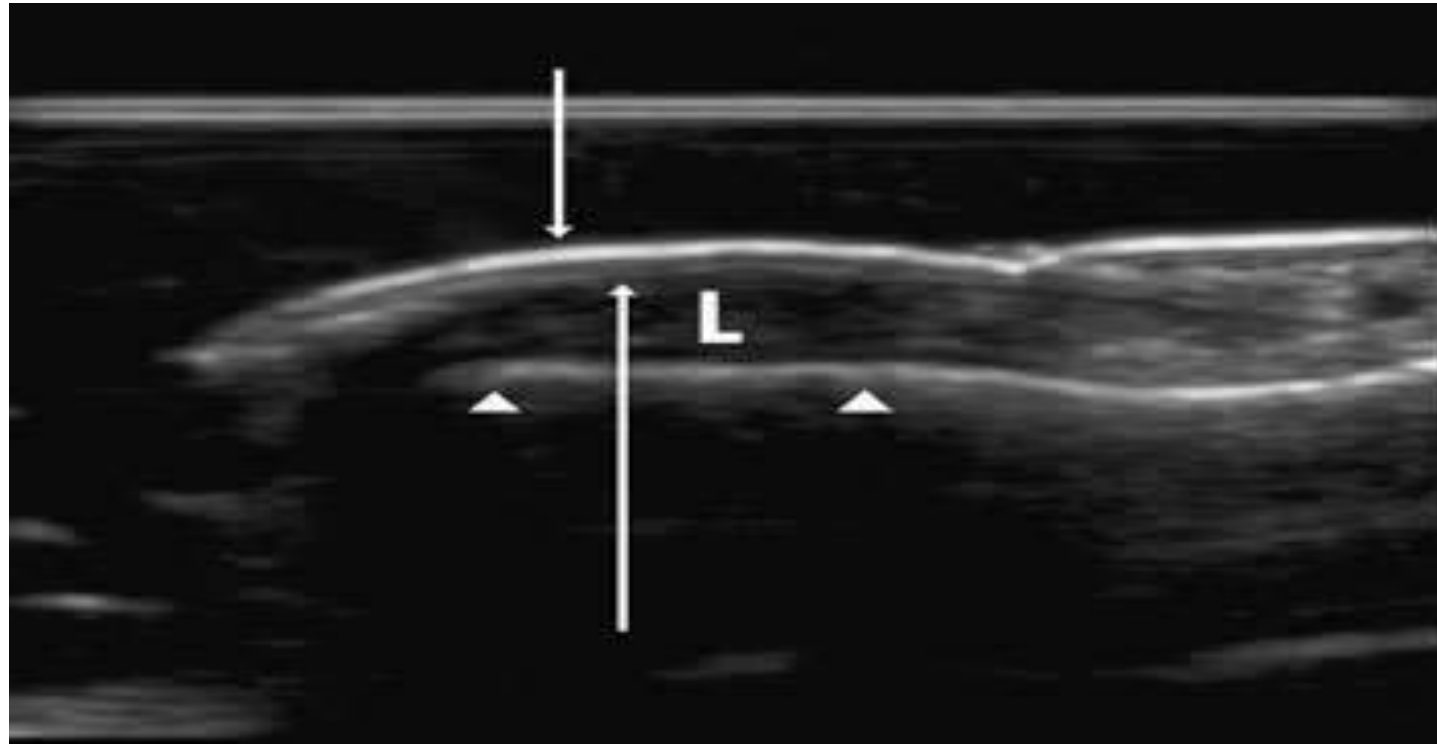
Four types in the order of lowest to highest engagement:

- Type I: Hyperechogenic plaques that only compromised the ventral plate with an undamaged dorsal plate
- Type II: Loss of definition of the ventral plate with effacement of its contours and normal-looking dorsal plate
- Type III: Wavy appearance of both nail plates
- Type IV: Loss of definition of both plates

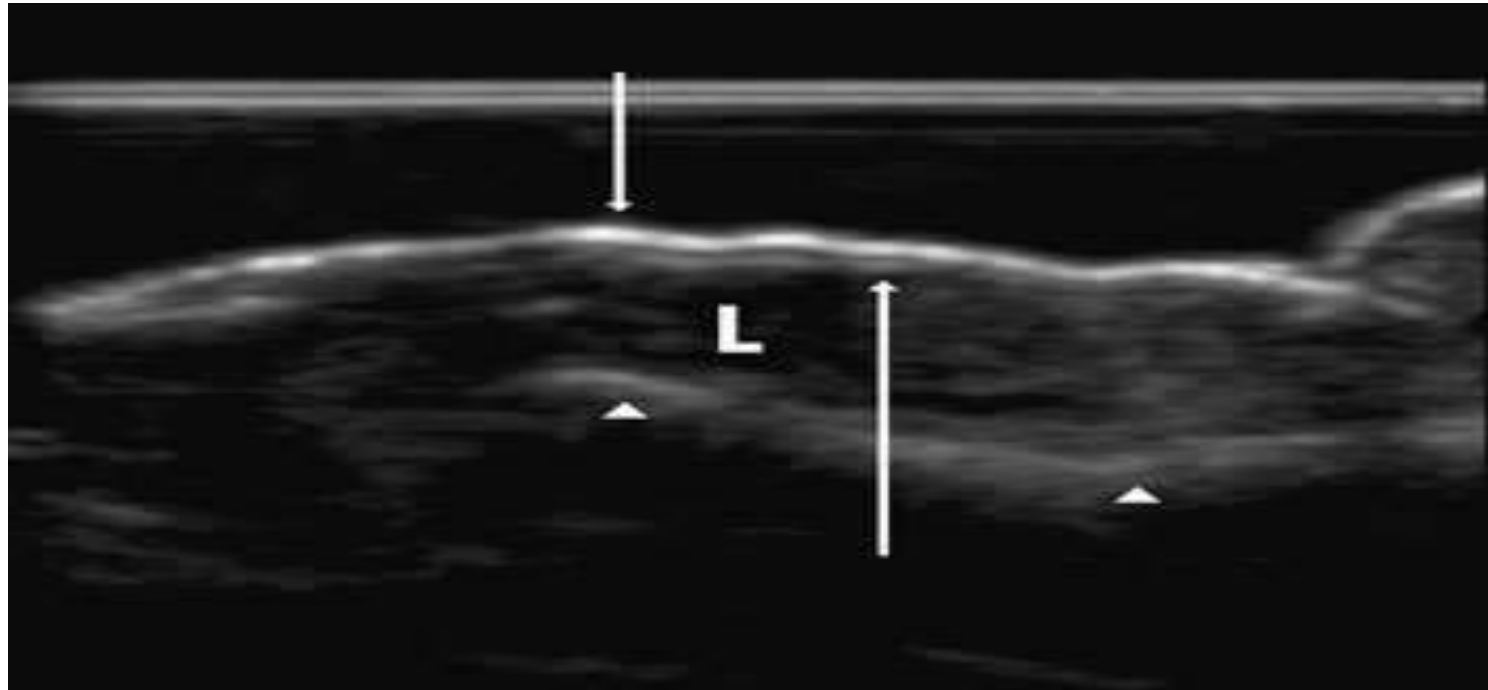
Wortsmann Type I



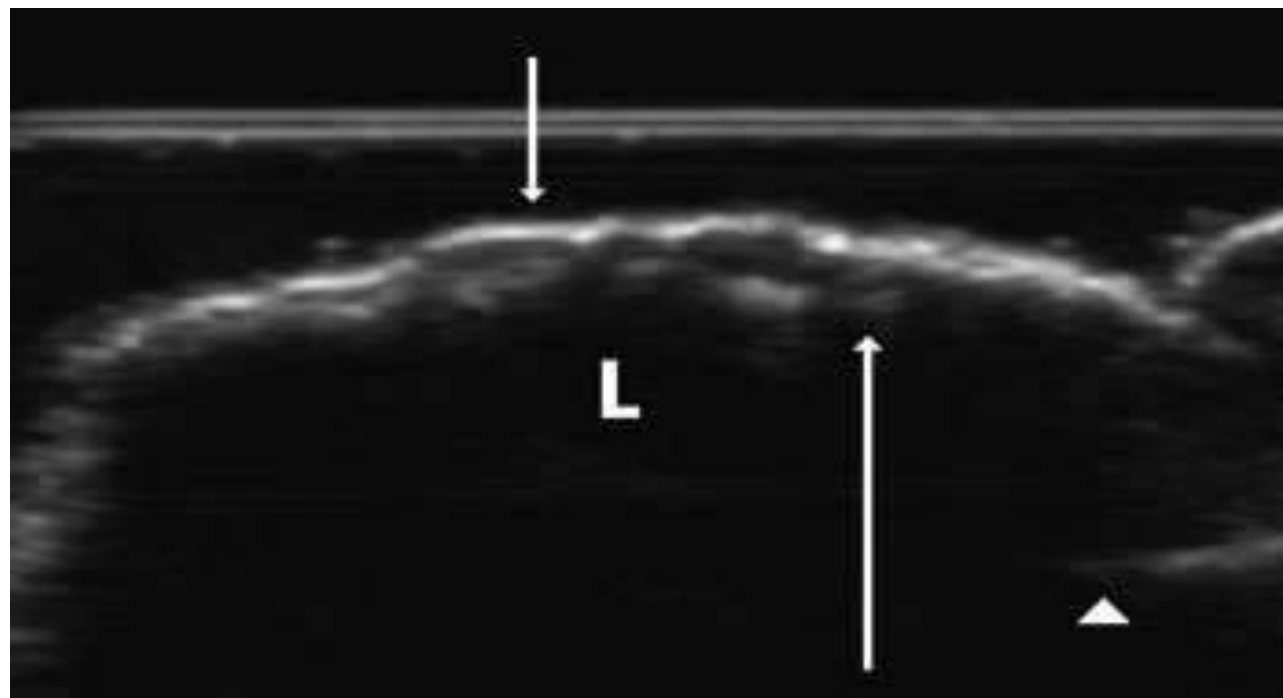
Wortsmann Type II



Wortzman Type III



Wortzman Type IV



Clinical Significance of Nail Plate Changes on USG Favoring Psoriasis

Rheumatology International
<https://doi.org/10.1007/s00296-018-4160-8>

Rheumatology
INTERNATIONAL

OBSERVATIONAL RESEARCH



Assessment of nail unit structures by ultrasound in patients with psoriatic arthritis and their correlations with disease activity indices: a case–control study

Sumantra Mondal¹ · Satarupa Dutta¹ · Debasish Lahiri¹ · Debanjali Sinha¹ · Geetabali Sircar¹ · Ashok Kumar Mandal² · Megha Kejriwal² · Alakendu Ghosh¹

Detected in 75.34% of clinically normal nails!

Nail Psoriasis vs Onychomycosis on Ultrasound

Ultrasound Assessment of Psoriatic Onychopathy: A Cross-sectional Study Comparing Psoriatic Onychopathy with Onychomycosis

Mireia MORENO¹, Maria Pilar LISBONA^{2,1}, Fernando GALLARDO³, Gustavo DEZA³, Marta FERRAN³, Caridad PONTES⁴, Jesús LUELMO⁵, Joan MAYMÓ² and Jordi GRATACÓS¹

¹Department of Rheumatology, ⁴Clinical Pharmacology and ⁵Department of Dermatology, Hospital Universitari Parc Taulí, Sabadell, ²Department of Rheumatology, Parc de Salut Mar, ³Department of Dermatology, Parc de Salut Mar, Universitat Autònoma de Barcelona/Universitat Pompeu Fabra, Barcelona, Spain

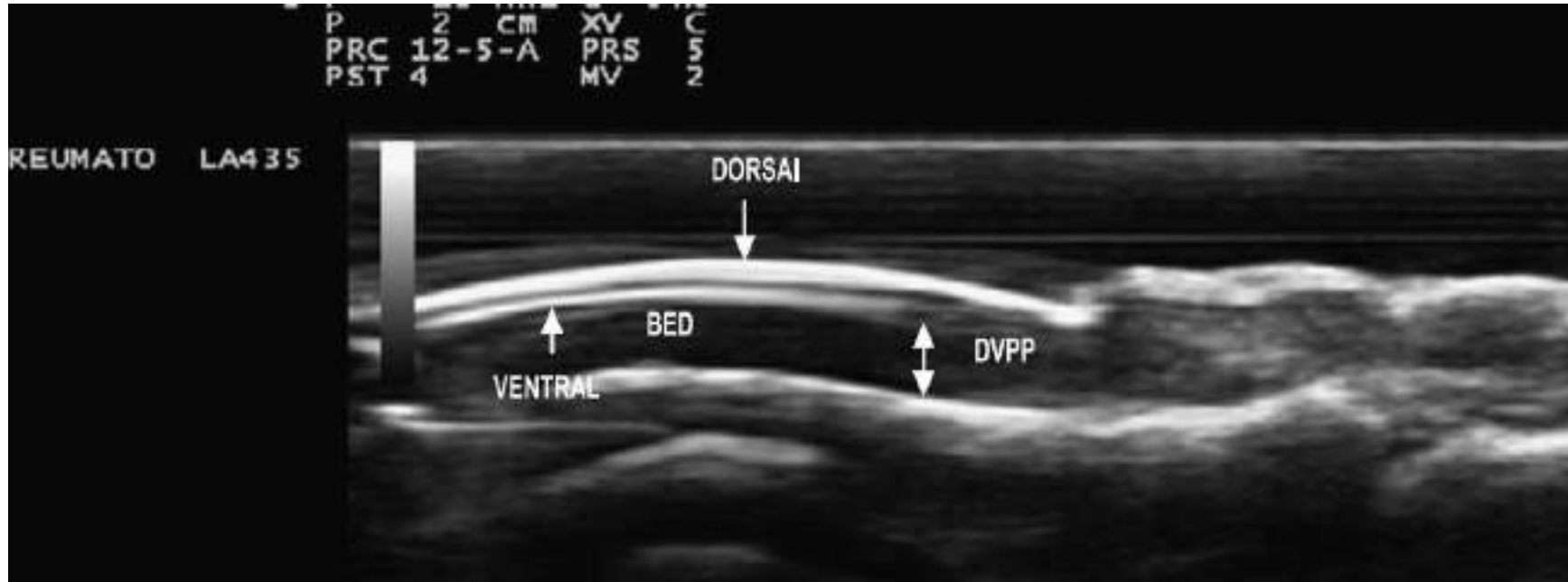
¹Dr Lisbona died just before completion of the study.

Features favoring nail psoriasis are:

- ✓ Grade or 2 higher PD signal (Sn = 22.9%, Sp = 96%)
- ✓ Structural damage of DIP joints, particularly erosion and cortical irregularity) (Sn = 62.8%, Sp = 75%)

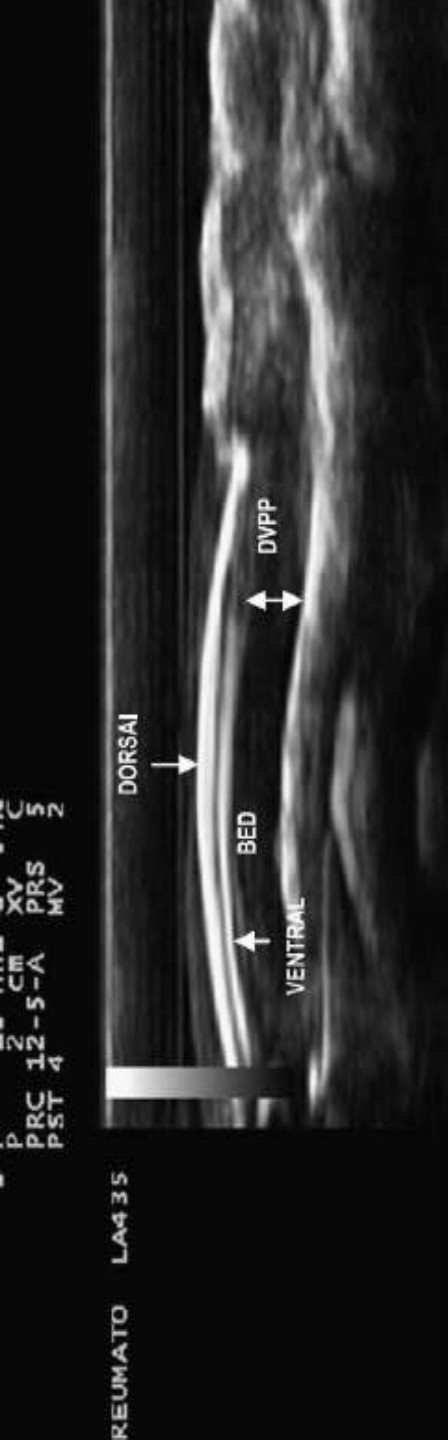
Onychomycosis may be present in up to 47.9% of cases with nail psoriasis

Distance between the Ventral Nail Plate and the Osseous Margin of the Distal Phalanx (DVPP)



Sandobal C, Carbó E, Iribas J, Roverano S, Paira S. Ultrasound nail imaging on patients with psoriasis and psoriatic arthritis compared with rheumatoid arthritis and control subjects. JCR: Journal of Clinical Rheumatology. 2014 Jan 1;20(1):21-4.

Comparison of DVPP across Different Groups



Diagnosis	Mean DVPP (SD)	ANOVA Test	Dunnet (Post-ANOVA Test)
Psoriatic arthritis	2.34 (0.55)	P < 0.0001	P = 0.001
Cutaneous psoriasis	2.28 (0.48)		P = 0.006
Rheumatoid arthritis	1.78 (0.25)		P = 0.548
Control subjects	1.90 (0.20)		–

Sandobal C, Carbó E, Iribas J, Roverano S, Paira S. Ultrasound nail imaging on patients with psoriasis and psoriatic arthritis compared with rheumatoid arthritis and control subjects. JCR: Journal of Clinical Rheumatology. 2014 Jan 1;20(1):21-4.

Clinical Application: DVPP Cut-off of 2mm (PsO & PsA vs RA & Healthy Controls)

Sensitivity: 80%

Specificity: 71%



Positive predictive value: 73%

Negative predictive value: 78%

Other Indications of Skin Ultrasound in Rheumatology

- ✓ Objective monitoring of skin thickness and stiffness in patients with systemic sclerosis
- ✓ Assessment of digital ulcers in patients with systemic sclerosis (power Doppler signals may be a hint to the presence of an infection)
- ✓ Differentiation between septal panniculitis and lobular panniculitis
- ✓ Assessment of morphea

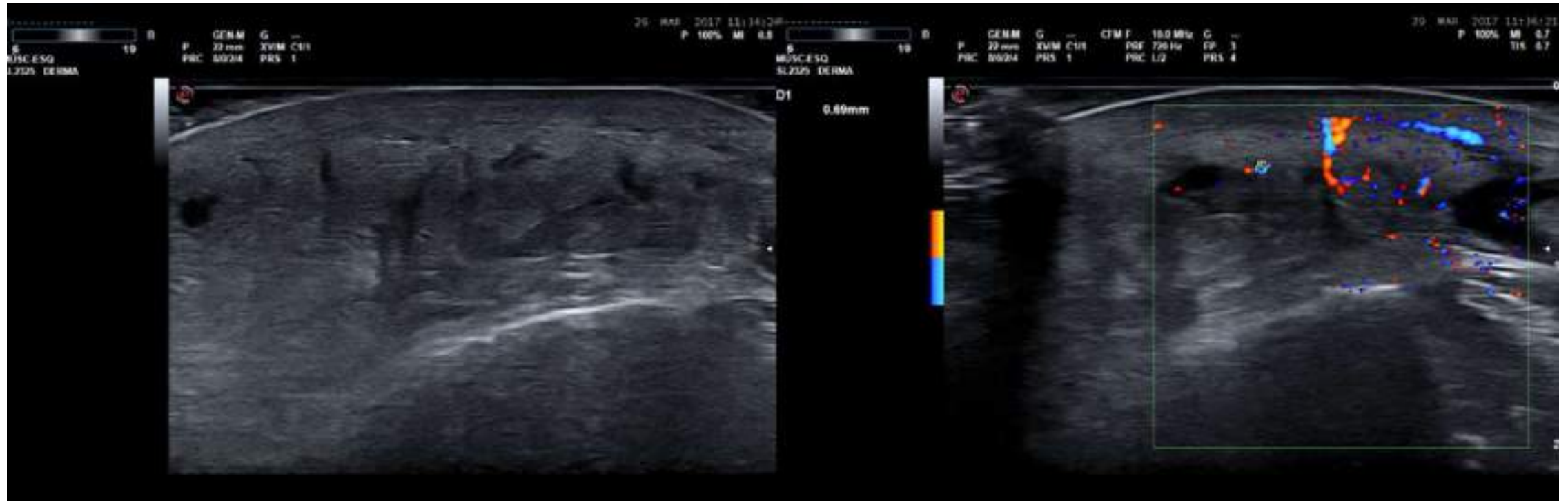
Inter- and Intra-rater Agreement of Dermatologic Ultrasound for the Diagnosis of Lobular and Septal Panniculitis

Jorge Romani, MD, PhD , Priscila Giavedoni, MD, Esther Roé, MD, David Vidal, MD, PhD, Jesús Luélmo, MD, Ximena Wortsman, MD, PhD 

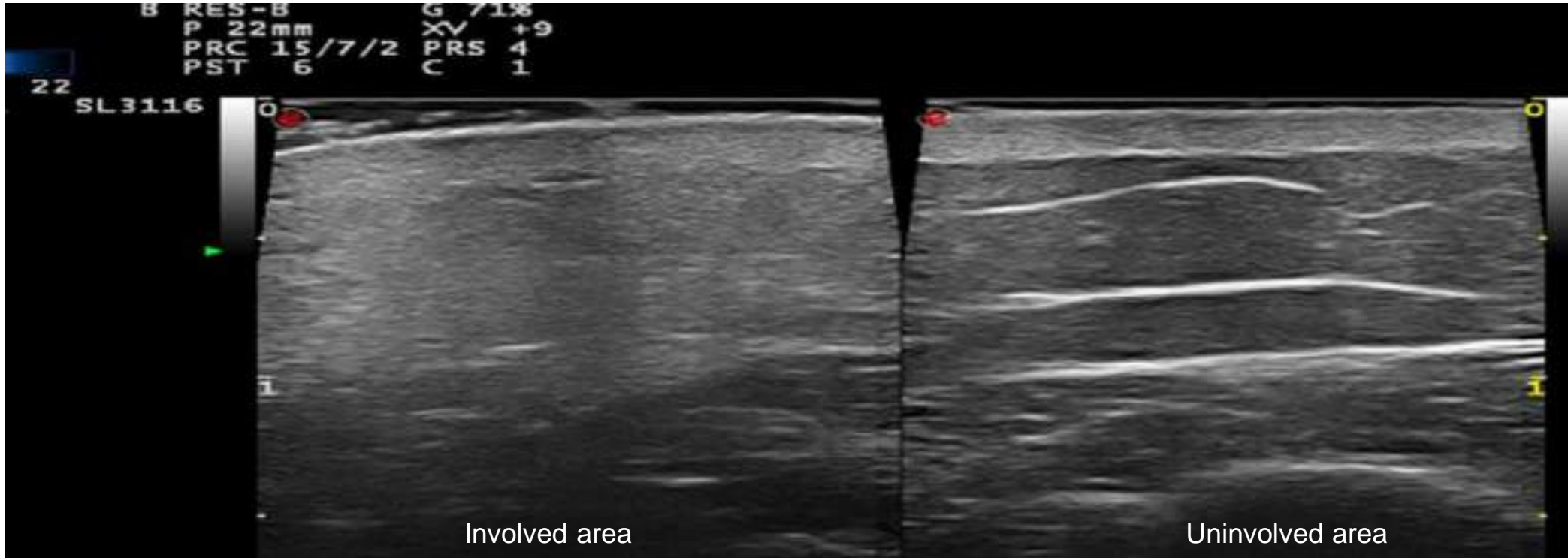
Septal Panniculitis	Lobular Panniculitis
<p>Septal thickening and hypoechogenicity (thickness ≥ 1 mm in 3 or more septa), preferably adjacent to different fat lobules, which was not easily compressible, with frequent hyperechogenicity of adipose lobules and an increase in Doppler flow.</p>	<p>Hyperechogenicity and blurriness of the adipose lobules, without the presence of septal thickening and hypoechogenicity, or an increase in Doppler flow. If an interlobular liquid collection is present, it should have been anechoic and easily compressible</p>

Sensitivity and Specificity of 85-90%

USG Features of Septal Panniculitis



USG Features of Septal Panniculitis

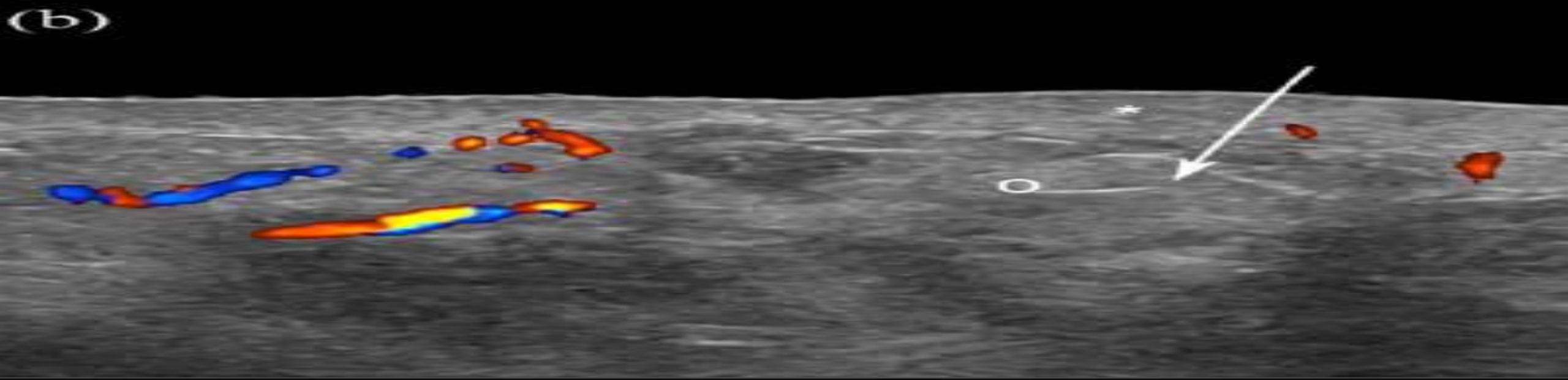
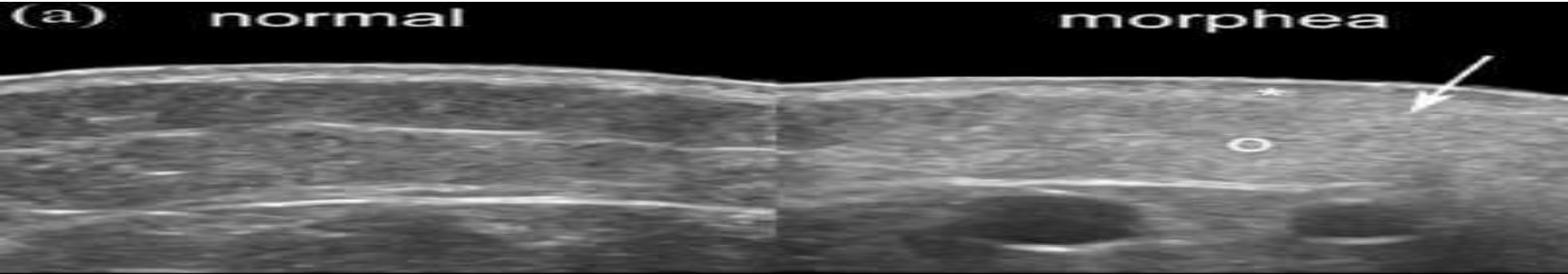


Ultrasound for Morphea

- Diagnosis
- Selection of the most appropriate biopsy site
- Monitoring
- Hydrodissection of entrapped nerves, e.g., the median nerve

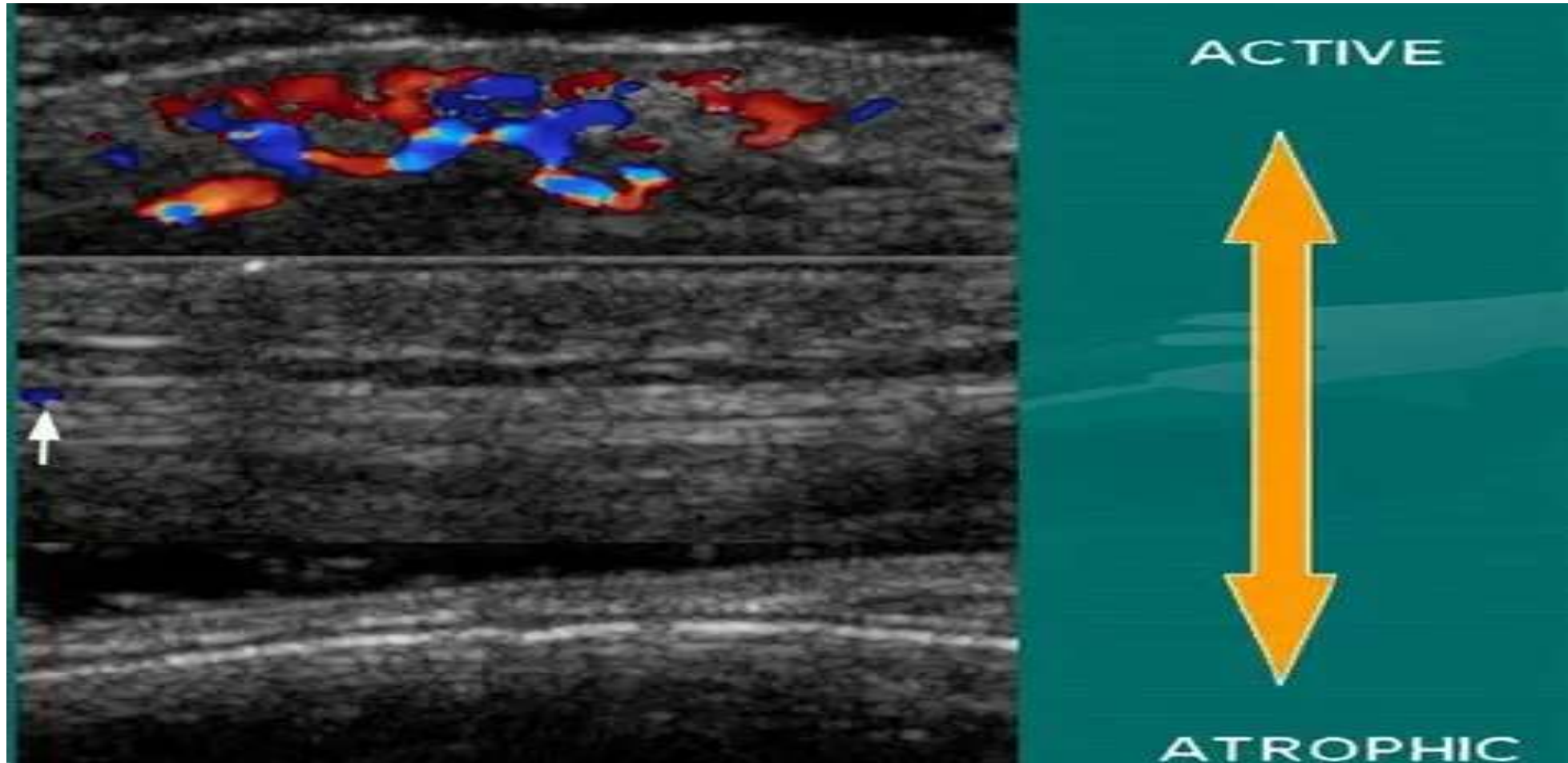
Wortsman X. Why, how, and when to use color Doppler ultrasound for improving precision in the diagnosis, assessment of severity and activity in morphea. *Journal of Scleroderma and Related Disorders*. 2019 Feb;4(1):28-34.

Active Morphea



morphea

Activity Phases of Morphea



Take-Home Messages

- ❑ Skin ultrasound has important roles in the clinical practices of both dermatology and rheumatology
- ❑ It allows objective monitoring of the response to the treatment of psoriasis
- ❑ Nail ultrasound may help to distinguish between RA and PsA
- ❑ Skin ultrasound has roles to play also in some other rheumatic diseases with skin manifestations

Thank

You

